

Wellen's syndrome (ST-T variant-clinician's dilemma)

Dhara Shukla*, Tamanna Charpot*, Uttam Pedhadiya*, Mihir Trivedi*, Parth Thakkar*, B.D.Mankad**

Abstract

Wellen's syndrome is a preinfarction clinical entity which describes characteristic ECG pattern which suggests high degree proximal LAD stenosis that will soon result in an acute anterior wall MI if patient is not urgently catheterised and occlusion is opened. This case report discusses an elderly male without any cardiac history with no chest pain came with lower abdominal pain and diagnosed to have urinary bladder calculi and was referred to us for preoperative fitness for open cystolithotomy and ECG changes. His ECG showed deep T wave inversion in V1-V5 with upward slopping of ST segment in V2-V5 (wellen's pattern). He was then transferred under cardiology unit and urgent CAG done and it showed 90% stenosis in proximal LAD and successful PTCA was done with placement of 2 drug eluting stents.

Keywords: ECG, LAD stenosis, ST segment, Wellen's syndrome

Introduction:

Wellen's syndrome is characterised by classic T waves found in precordial leads especially V2-V3. Wellen's syndrome (widow maker) or alternatively known as anterior, descending, T wave syndrome describes characteristic biphasic or deeply inverted T waves in a patient during pain free period which is indicative of critical stenosis of proximal LAD which should be opened early otherwise will result in acute MI within few days or weeks.⁽¹⁻⁴⁾

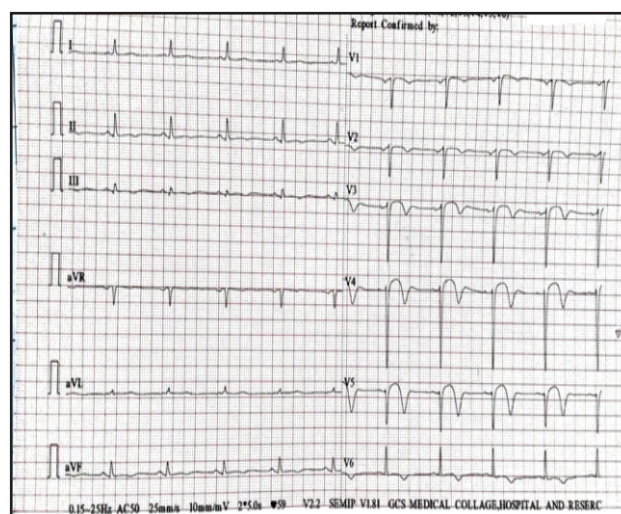
Case discussion:

A 65 year old male chronic smoker, came with complains of lower abdominal pain and difficulty in micturition since 15 days. He was investigated and found to have mobile urinary bladder calculi (16 mm) and enlarged prostate with changes of cystitis. Patient was posted for open cystolithotomy for the same. For pre operative fitness and ECG changes, medicine reference was given. On examination patient was conscious, cooperative, oriented to time, place and person. Temperature was normal, Pulse-78/min, Blood pressure-130/82 mm Hg, SpO₂-98% on room

air, respiratory system, cardiovascular system, central nervous system and gastrointestinal system examination were normal. Patient had no complaint of

ECG ON EVALUATION:

Figure 1 : Deeply inverted T waves in V1-V5



chest pain/palpitation/perspiration / giddiness / gabharaman/lower limb oedema/syncope. Patient had no past history of hypertension /diabetes mellitus/hypercholesterolemia. No significant family history of premature heart disease / hypertension / diabetes mellitus. Patient's ECG was done and was showing deeply inverted T waves in V1-V5 with upward slopping of ST segment in V2-V5.

* Resident,

** Professor, Department of General Medicine, GCS Medical college, Hospital & Research Centre, Ahmedabad, Gujarat, India

Correspondence : Dr. Dhara Shukla

E-mail : dhara.a.shukla@gmail.com

Figure 2: Findings of Coronary angiography (pre-stenting)

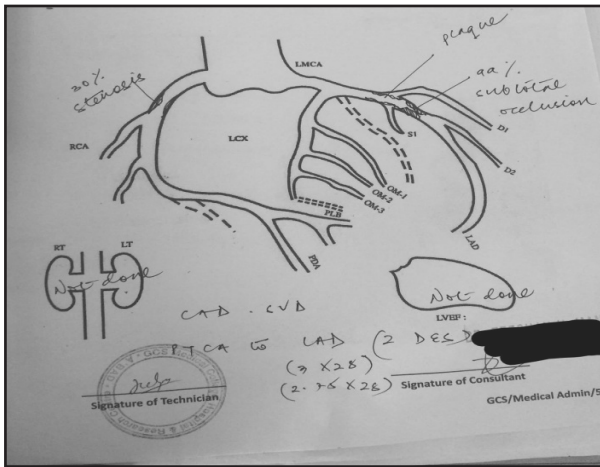


Figure 3 : Pre-stenting LAD artery presentation

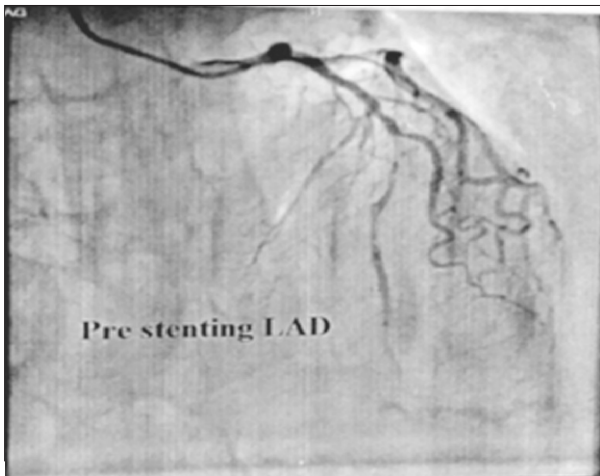


Figure 4 : Post-stenting LAD artery Presentation

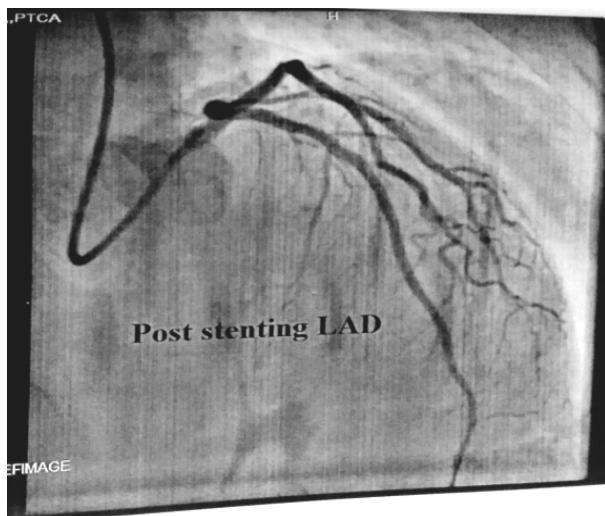


Figure 5 : Post PTCA ECG presentation

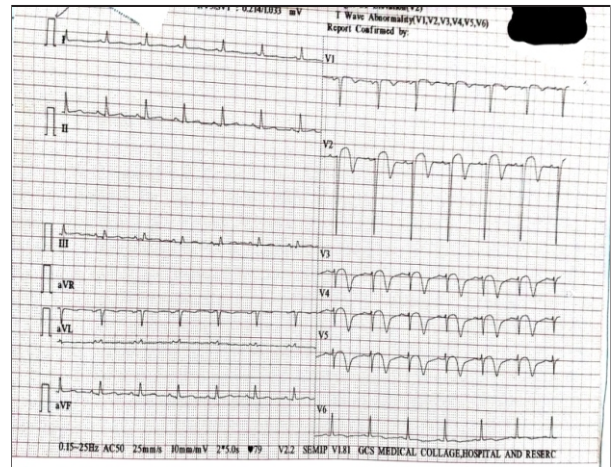


Figure 6 : findings of PTCA to LAD (2 DES)

Date: 08-06-2021	Procedure No.: 377
Route: Right Radial	SPO ₂ : 100%
HR: 78 / min	ID No.: 1130763
AO Pressure: 70/59 mmHg	
Sheath: 6F	

TARGET VESSEL	LAD
GUIDING CATHETER	EBU 6F
GUIDE WIRE	Runthrough
PRE DILATATION BALLOON	2 x 12 mm Apollo
STENT	2.75 x 32 mm, 3 x 32 mm Racer CC
POST DILATATION BALLOON	3 x 12 mm NCTREK
No. OF INFLATION	4
SITES OF INFLATIONS	Proximal to distal LAD
MAXIMUM PRESSURE	22 atm
MAXIMUM DURATION	8 sec

FLOW TIMI	
PRE PTCA	99%
POST PTCA	0%
POST STENT	0%

FINAL DIGNOSIS: Successful PTCA to LAD (2 DES) done.

POST ANGIOPLASTY CAG:

His complete blood count, renal function test, liver function test were normal. Troponin I was sent and it was mildly elevated-0.05 ng/ml(0-0.02) and CK MB - 125 u/l(10-25). His 2 D echocardiography was showing concentric left ventricular hypertrophy, normal ejection (55%), no regional wall motion abnormality. Patient's relatives had been explained about immediate need of coronary angiography and which suggested single vessel disease-90% subtotal occlusion of left anterior descending artery and was advised for angioplasty. PTCA to left anterior descending artery was done (2 drug eluting stents were kept).

Patient was stable hemodynamically post PTCA and was discharged with oral antiplatelets, statins, beta-blockers and diuretics.

Discussion:

In early 1980s, Dr. DeZwaan, Dr. Wellens and colleagues identified Wellen's syndrome and noted 75% patients with this type of ECG findings developed extensive anterior wall MI if treated conservatively.⁽⁹⁻¹¹⁾ Wellen's syndrome can be presented with 2 types of ECG patterns—deeply inverted T waves and biphasic T waves. These T waves represent reperfusion of myocardium. This type of ECG pattern is suggestive of significantly stenosed Left anterior descending artery which should be opened immediately otherwise may result in extensive anterior wall MI within few days or weeks.

Diagnostic criteria for Wellen's syndrome are as follows:

- Deeply inverted T waves in leads V2 and V3 (may also be seen in leads V1, V4, V5, and V6) OR biphasic T waves (with initial positivity and terminal negativity) in V2 and V3.⁽⁶⁻⁸⁾

Plus

- Isoelectric or minimally elevated ST segment, less than 1 mm (in other words, no signs of an acute anterior wall myocardial infarction)
- Preservation of precordial R-wave progression AND no precordial Q waves (in other words, no signs of old anterior wall infarct)
- Recent history of angina
- ECG pattern present in a pain-free state
- Normal or slightly elevated cardiac markers

Type A (25%): deeply inverted T waves in V2-V3

Type B (75%): biphasic T waves in V2-V3

T waves inverted with ST segment elevation or depression or isoelectric.^(12,13)

V1-V3 are diagnostic leads corresponding with lesion between 1st and 2nd septal branches of LAD.

Cardiac enzymes will be normal or mildly elevated.

Etiology:

- Increased cardiac demand
- Atherosclerotic plaque
- Hypoxia

The Risk factors for the same are DM, HT, increased age, increased cholesterol, family history of premature heart disease, occupational stress, smoking and metabolic syndrome.

Understanding T wave changes:

Following sequence of events is thought to occur

- sudden occlusion of LAD - transient anterior wall MI with chest pain and diaphoresis (not captured in ECG)
- reperfusion of LAD - due to spontaneous lysis of clot or prehospital aspirin - resolved chest pain - biphasic/inverted T waves
- Three possibilities:
 1. Artery remains open—deeply inverted T waves but LAD can reocclude at any time and apparent normalisation of T waves (pseudonormalization) and prominent T waves and hyperacute anterior wall MI (recurrence of chest pain).
 2. If artery remains occluded—evolving MI
 3. Stuttering pattern - due to intermittent reocclusion and reperfusion

Differential diagnosis:

Deep T wave inversion can be seen in Cerebral T waves, LVH, RBBB, HOCM and pulmonary embolism.

Pseudo Wellen's syndrome:

- Cocaine use—coronary vasospasm especially in young male—when cocaine is cleared from body ECG will be normal, beta-blocker is detrimental due to potential unopposed action of alpha receptors

- Marijuana use
- Takotsubo cardiomyopathy- due to myocardial edema
- Myocardial bridging- LAD stenosis

Treatment:

Early intervention in the form of revascularisation of LAD is mandatory.^(4,5,7) Patient should be given antiplatelet, anticoagulation, nitrates, beta-blocker. Stress test is contraindicated.

Conclusion:

Wellen's syndrome is diagnosed with characteristic ECG findings interpreted by good clinician even in absence of chest pain and non significant increase in cardiac enzymes and should be promptly tackled with urgent cardiac catheterisation to prevent extensive anterior wall infarction.

References:

1. Ramanathan S, Soaly E, Cherian A, Heidous MA. 'T' twist: Wellens syndrome. *QJM*. 2019 May 01;112(5):373-374. (PubMed)
2. Singh D, Suliman I, Chyshkevych I, Dabage N. A Pathognomonic Electrocardiogram That Requires Urgent Percutaneous Intervention: A Case of Wellens Syndrome in a Previously Healthy 55-Year-Old Male. *Am J Case Rep*. 2019 Jan 28;20:117-120. (PMC free article) (PubMed)
3. Wang X, Sun J, Feng Z, Gao Y, Sun C, Li G. Two case reports of Wellens' syndrome. *J Int Med Res*. 2018 Nov;46(11):4845-4851. (PMC free article) (PubMed)
4. Marzlin KM. Wellens Syndrome. *AACN AdvCrit Care*. 2018 Fall;29(3):360-364. (PubMed)
5. Yasin OZ, Rubio-Tapia A, Sarano ME. Wellens Syndrome with Syncope but Not Chest Pain. *Cardiology*. 2017;137(1):9-13. (PubMed)
6. Udechukwu N, Shrestha P, Khan MZ, Donato AA. Wellens' syndrome: a close call. *BMJ Case Rep*. 2018 Jun 21;2018. (PMC free article) (PubMed)
7. Ramires TG, Sant'Anna J, Pais J, Picarra BC. Wellens' syndrome: a pattern to remember. *BMJ Case Rep*. 2018 Apr 10;2018 (PMC free article) (PubMed)
8. Grautoff S. Wellens' syndrome can indicate high-grade LAD stenosis in case of left bundle branch block. *Herzschrittmacherther Elektrophysiol*. 2017 Mar;28(1):57-59. (PubMed)
9. De Zwaan C, Bär FW, Janssen JH, et al. Angiographic and clinical characteristics of patients with unstable angina showing an ECG pattern indicating critical narrowing of the proximal LAD coronary artery. *Am Heart J* 1989; 117:657-665.
10. Movahed MR. Wellen's Syndrome or Inverted U-waves? *ClinCardiol*. 2008;31:133-4. - PMC - (PubMed)
11. Smith S, Whitwam S. Acute Coronary Syndromes. *Emerg Med Clin N Am*. 2006;24:53-89. - (PubMed)
12. Nisbet B, Zlupko G. Repeat Wellen's syndrome: Case report of critical proximal left anterior descending artery restenosis. *J Emerg Med*. 2008. - (PubMed)
13. Sobnosky S, Kohli R, Bleibel S. Wellen's Syndrome. *Int J Cardiol*. 2006;3:1.