

Malignant Transformation in Mature Cystic Dermoid: A Case Series of 8 Cases

Bhavana Sontakke(Ingle)*, Chetana Parekh**, Shilpa M Patel***, Ruchi Arora**

Abstract :

Introduction: One of the most common types of ovarian germ neoplasm is Mature cystic teratoma(MCT) which accounts for almost 20% of all ovarian neoplasm. **Objective:** Analyze patients with Malignant Transformation (Mt) arising from Mature Cystic Teratoma of the ovary to evaluate Clinico-pathological features and treatment modalities. **Methods:** This is an observational study of 8 patients of Mt in MCT, who had taken complete treatment at GCRI between the period from September 2016 to September 2021. During this observation period, a total of two thousand one hundred and seventy seven ovarian tumors were diagnosed. Out of these patients, 9.32% (203) were MCTs. Of the consecutive cases of 203 ovarian MCTs diagnosed, 3.9% (8) had Mt of MCT, which was our study group. **Results:** The mean age of patients with Mt in MCT was 47.1 years (27- 65 yrs), while mean age of the patients with MCT was 42 years (35-55 years). Among the 21 postmenopausal, MCT's 28.5% (6) cases developed Mt and only 1% i.e., two cases from premenopausal showed Mt. Abdominal pain as main symptom was seen in 87.5% (7/8) patients. The duration of symptoms ranged from 3 to 6 months. CA125 was elevated in 75% patients. Germ cell markers including beta HCG, AFP, LDH were found to be normal. **Conclusion:** Diagnosis of malignant transformation of MCT is very difficult. There should be high index of suspicion of malignant transformation if the MCT has been present for a long time; the patient is postmenopausal, age>45 yrs; the tumor diameter is greater than 9.5 cm; or there is thickening of the cyst wall or papillary growth occurs, increased tumor markers.

Keywords: Cystic dermoid, Malignancy, Mature Cystic Teratoma, Ovarian neoplasm

Introduction:

Mature cystic teratoma (MCT) of the ovary is the most common type of ovarian germ cell neoplasm. It comprises approximately 20% of all ovarian neoplasms. ^(1, 2) Malignant transformation (Mt) is an uncommon consequence of a MCT and it occurs in approximately 1-3% of all MCT cases, as per one report the frequency was as high as 6.67%. The common symptoms of benign MCT include abdominal mass, swelling, and pain. Preoperative diagnosis of MCT of the ovary is relatively easy due to the advances in radiology. On the other hand, the absence of specific signs and symptoms indicating a Mt, their similarity to MCT in presentation and their rare occurrence makes it difficult to diagnose such

transformations pre-operatively. ⁽³⁻⁵⁾ Hence, Mt in MCT is detected postoperatively by pathological examination in majority of cases. In earlier studies, these tumours showed a very poor prognosis, with the majority of patients dying within 12 months of diagnosis, most of which were in advanced stage. ^(3, 4) Because of the rare occurrence, there have been very few studies published of Mt in MCT which concern the clinical pathology of MCT with Mt and thus no consensus regarding optimal management protocol for these has been established till date except operative interference.

The most common malignant tumour arising from MCT is squamous cell carcinoma (SCC), however, adenocarcinomas, carcinoid tumours, melanomas, soft tissue sarcomas, basal cell carcinoma, sebaceous tumor, malignant melanoma, and neuroectodermal tumor are also seen. We retrospectively analysed eight patients with Mt arising from MCT of the ovary to evaluate clinico-pathological features and treatment modalities.

* Fellow,

** Professor,

*** Professor & Head.

Department of Gynaecological Oncology,
Gujarat Cancer & Research Institute (GCRI),
Civil Hospital Campus, Ahmedabad, Gujarat, India

Correspondence : Dr. Chetana Parekh

E-mail : chetna.parekh@gcriinida.org

Materials and Method:

This is an observational study of 8 patients of Mt in MCT, who had taken complete treatment at GCRI between the period from September 2016 to September 2021. During this observation period, a total of two thousand one hundred and seventy seven (2177) ovarian tumors were diagnosed. Out of these 2177 patients, 9.32% (203) were MCTs. Of the consecutive cases of 203 ovarian MCTs diagnosed, 3.9% (8) had Mt of MCT, which was our study group. We excluded the patients who did not complete the treatment. The clinical records of all these patients were evaluated in terms of age, parity, presenting symptoms, serum tumour markers, intraoperative findings, and adjuvant treatment. The mean age and size of the tumors were noted among all these patients with Mt in MCT and compared with those of MCT. The morphological and clinico-pathological features of these malignant transformations in MCT of the ovary were analysed. Routine physical examination, serum tumour marker, ultrasonography, chest X-ray, and CT or MRI if necessary was performed for initial diagnosis and postoperative follow-up.

Results:

The mean age of the patients with Mt in MCT was 47.1 years (27- 65 yrs), while the mean age of the patients with MCT was 42 years (35-55 years) (Table 1). Out of 203 cases of MCT, 10.34% (21), were postmenopausal and 90% (182) were premenopausal (<40 years). Among the 21 postmenopausal, MCT's 28.5% (6) cases developed Mt and only 1% i.e., two cases from premenopausal showed Mt. (Table 1). Abdominal pain as main symptom was seen in 87.5% (7/8) patients. The duration of symptoms ranged from 3 to 6 months except in one patient, who presented with acute pain. Ca125 was elevated in 75% (6 out of 8 patients). Germ cell markers including beta HCG, AFP, LDH were checked in patients <40 yrs, were found to be normal. No other significant markers are raised (CEA, CA19-9).

In patients with MCT the mean tumor size was 6.4 cm (3.3–17 cm) with bilaterality seen in 4% cases. The mean tumor size in Mt with MCT was 11.4 cm (range 9 to 13 cm). The size of carcinomatous components in the tumor, which had been measured by the preoperative image examination, was 3.35 cm (range, 1.4 to 4.2 cm). None of the tumors were bilateral.

Table 1 : Comparison of selected variables in Mature Cystic Teratoma (MCT) versus Malignant transformation in MCT

Sr. No.	Variables	Mature Cystic Teratoma (MCT)	Malignant transformation in MCT
1	Mean Age in years	42	47
2	Mean Size in cms	6.4	11.4
3	Symptoms	Abdominal lump	Abdominal pain
4	Treatment	Exploratory laparotomy	Exploratory laparotomy with complete staging f/b adjuvant treatment as required
5	Radiology	Ovarian or pelvic solid-cystic lesions with uneven density with typical features of teratoma.	Occasional fat stranding in 2 cases, One case- lesion abutting adjacent bowel loops, left common iliac vessel with loss of fat planes. In all- the solid component was enhanced, with unclear demarcation of the lesions.

Almost all tumors presented as predominantly cystic lesions on imaging with occasional fat stranding seen in two patients. Two patients showed fat fluid levels and internal air foci and one lesion showed exophytic growth. Out of 8 patients, only one case was radiologically advanced as it showed the lesion abutting adjacent small bowel loops & left common iliac vessels with loss of fat planes. Two patients presented with skin metastasis in the form of fistula. Of these, one patient had undergone laparoscopy with removal of ovarian tumor, she came with skin metastasis at port site with draining fistula formation. The other patient developed skin metastasis and fistula at the biopsy site on skin, as biopsy was done in view of advanced disease radiologically and clinically.

Fig. 1 : Squamous transformation in mature cystic dermoid with atypical mitotic changes

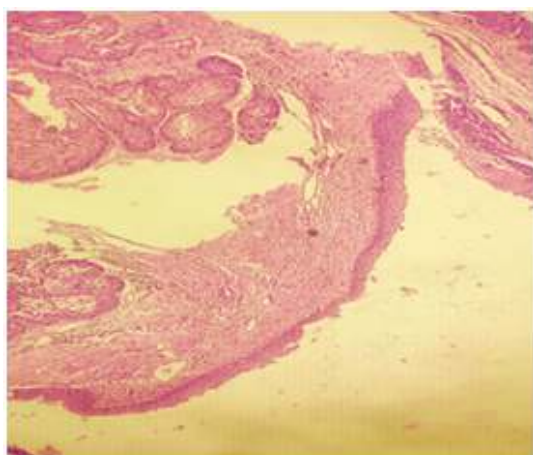


Fig.2 : Adenocarcinoma with glands and mitotic changes

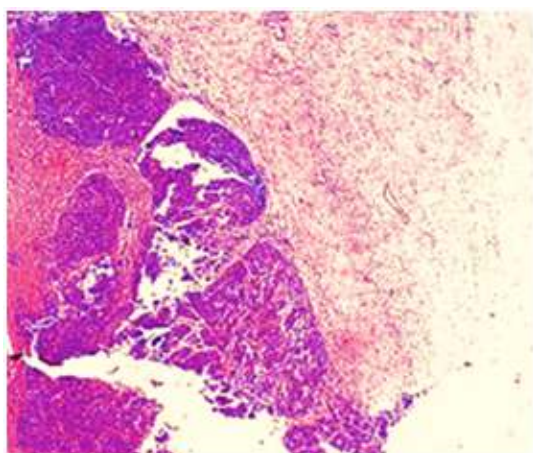
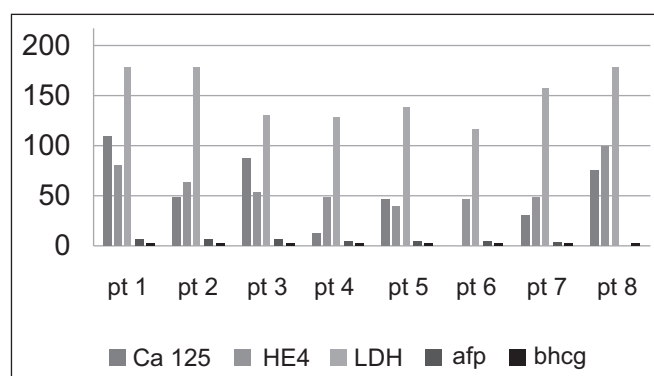


Fig. 3 : Tumor markers in malignant transformation in MCT



Six patients underwent exploratory laparotomy and surgical staging at our institute. Specimen was sent for frozen section and surgery completed accordingly. One patient who presented with skin fistula received NACT followed by interval debulking surgery. The second patient was given chemotherapy in view of advanced disease but the patient denied surgery and hence received only chemotherapy. FIGO staging was done in all patients. On FIGO staging, five were stage IA, one case was stage IIIC and two were stage IV B.

Histopathologically, SCC-Mt was seen in 87.5% i.e. seven out of eight and Mucinous adenocarcinoma was seen in 12.5% i.e. one patient. Based on the final histopathological report, patients in early stage were kept under strict surveillance, patients with advanced stages received adjuvant chemotherapy (paclitaxel-carboplatin regime). None of the patients received the radiation therapy.

Discussion:

Mt in CT is exceedingly rare and occurs in only 1-3% of cases.^(5,6)

In our study the frequency of Mt in MCT was 3.9% which is similar to the reported literature, by Kikkawa et al at 3.5%., who studied 37 cases of SCC arising from MCT in a 17-year period.⁽⁷⁾

As shown in our study and various other studies, Mt into SCC is the most common type. In our study, the average age of MCT was from 32.7 to 37.5 years, whereas the average age for Mt in MCT was 50.8 to 55.2 years. Results were similar to those seen by

Table 2 : Correlation of tumor markers with clinical presentation and other selected variables among study participants

Comparative findings of selected variables								
Sr. No.	Age	Laterality	Clinical features	Tumor Markers	Size (in_)	Histopathological diagnosis	Stage	Treatment received
1	58	Unilateral _left	Abdominal pain, Sking, lesion with draining sinus	Ca125: 79.6/He4: 80.53/Hcg: 8.34/Cea: 2.16/Ldh: 180.4/Afp: 5.04/Ca 19-9: 0.924	21.0x12.0x 8.0	SCC	IV B	Exploratory lap-adjvant
2	65	Unilateral _left	Abdominal pain	Ca125: 48.85/He4: 64.75/Hcg: 4.87/Ldh: 180.4/Afp: 5.	87x65	SCC	IA	Staging lap observation
3	27	Unilateral _left	Abdominal distention & pain	Ca125: 88.84/He4: 64.75/Hcg: 4.87/Ldh: 180.4/Afp: 5.	9.5x7x6	SCC	IA	Staging lap observation
4	53	Unilateral _left	Abdominal pain	Ca125: 12.2/He4: 48.48/Hcg: 1.61/Afp: 3.14	7.3x7.8	SCC	IIIc	Nact-IDS adjuvant
5	47	Unilateral _left	Draining sinus from left laparoscopic port site.	Ca125: 46.54/He4: Hcg: 0.1/Afp: 1.08	8.6x7x5.9	SCC	IVB	Chemotherapy alone*
6	47	Unilateral _left	Abdominal pain Anorexia	Ca125: 6.35/He4: 46.71/Hcg: 0.913/Afp: 2.77	9x7	SCC	IA	Staging lap-observation
7	49	Unilateral _left	Abdominal pain	HE4 48.1 pmol/L Ldh 159	40x47	SCC	IA	Staging lap-observation
8	45	Unilateral right	Abdominal pain	-	10x9	Adenocarcinoma	IA	Adjuvant chemotherapy

Kashimura et al. and other previous studies. In our series, most of the malignant transformation in MCT was seen in post-menopausal age group(>40 years) except one which was in pre-menopausal age (<40 years). The mean age of the patients with MCT was 42 years, while the mean age of the patients with malignant transformation in MCT was 47 years, which is slightly younger as compared to Kikkawa et al.⁽⁷⁾ where mean age of patients with malignant transformation was 55.2 years. Kashimura et al. showed the patient's age was a factor determining Mt

in MCT. The age of the patients was found to be positively correlated with the malignancy status and stage, indicating that the tumor becoming malignant increases with the increase in age as shown in our study. The incidence of malignant change in the postmenopausal age group was 28.5% in our study which is higher than compared to study by Wei et al. where it was only 15%.⁽⁸⁾

As per our study the mean sizes were 11.4 cm for patients with Mt MCT and 6.4 cm for MCT, which is similar to the study done Kikkawa et al. Chen et al.

studied 188 patients with Mt of MCT where the size of 78.7% of tumors was greater than 10. Malignant teratomas are often large, mostly unilateral, and have a diameter of 10 to 20 cm. Sensitivity for malignant transformation is 86% as seen in our study, when the tumor's diameter is greater than 9.9 cm. Thus the observation that the size of the tumor has an association with Mt. Our study findings and previous numerous studies suggest that, when a patient older than 45 years (postmenopausal), the diameter of the tumor is greater than 9.9 cm, and radiological adherence with surrounding tissues, the possibility of malignant transformation should be highly suspected. Owing to the lack of specific symptoms suggestive of Mt in MCT, these above criteria may be helpful to have a high suspicion of Mt in MCT.

Making a definite diagnosis of malignant transformation of MCT preoperatively is difficult.

Reports have shown that an imaging examination of patients with a malignant change in the tumor shows certain characteristic manifestations. Emoto M et al. studied transvaginal color Doppler ultrasonic characterization of benign and malignant ovarian cystic teratomas. The diagnostic value of computed tomography and magnetic resonance imaging examinations is important when identifying malignant manifestations, such as bleeding, necrosis, cyst wall growth, invasion of surrounding structures, or the occurrence of pelvic abdominal metastases.

Park JY et al. studied 16 patients with Mt in MCT, and concluded that MCT lacks tumor markers with high specificity and strong sensitivity similar to our present study where tumor markers were not significantly elevated in the patients. In previous studies, the preoperative diagnostic value of multiple tumor markers, such as CA 125, CA 19-9, CEA, SCC

Table 3: Comparison of findings of current study with similar studies

Study No.	Author (year)	Duration of study year	Percentage of Mt	No.	Mean age	Mean size	Clinical Presentation	Types of Common	Most
1	Ulker et al. (2012) ⁽³⁾	9	1.9	6	43	11.5	Pain	SCC, Cd, M Ad	SCC
2	Harshmohan ⁽⁴⁾ et al. (2007)	6	6.67	5	46	11.6	Pain	SCC, PTC	SCC
3	Rim et al. (2006) ⁽¹³⁾	20	1.7	11	50.6	NA	Lump	SCC, Ad	SCC
4	Ruchi Rathore, Sonal Sharma et al (2018) ⁽²⁴⁾	25	3.5	8	44	11.7	Pain	SCC, TCC, MM, Ad	SCC
5	Sakuma et al. (2010) ⁽¹⁸⁾	18	NA	37	52.5	8.8	NA	SCC, Ad, ASca, MM	SCC
6	Araujo et al. (2015) ⁽¹⁹⁾	5	5.5	10	36	NA	NA	SCC, PTC ASca, Ad, WD N Ca	SCC
7	Oranratanaphan et al.(2013) ⁽²⁰⁾	10	1.46	11	41.2	14.1	Lump	SCC, M Ad, Ad	SCC=M Ad
8	Fu Fan et al. (2013) ⁽²¹⁾	48	8	3	48	16	NA	SCC	SCC
9	Futagami et al. (2012) ⁽²²⁾	7	2.6	2	42.5	10	Lump	SCC	SCC
10	Black et al. (2015) ⁽²³⁾	8	1.2	7	53.7	18	Bloating, pain	M Ad, MM, SCC, PD Ad	M Ad
11	Our study at GCRI	5	3.9	8	47	11.4	Pain, lump	SCC, ad	SCC

MT-malignant transformation, CL/F-clinical features, NA-not available, SCC-squamos cell carcinoma, Cd carcinoid M Ad-mucinous adenocarcinoma, Ad-adenocarcinoma, PTC-papillary thyroid carcinoma, ASca-adenosquamous carcinoma, WDNCa-well differentiated neuroendocrine carcinoma

antigen, and AFP, was limited in MCT with Mt as in our study where none of the tumor markers were raised.

Rim et al.¹³ hypothesized that since 80% of benign MCTs are diagnosed during reproductive age, Germ cell tumors are thought to arise from primordial germ cells. Benign mature cystic teratomas are usually diagnosed at least 15-20 years before their malignant transformations, and thus a possibility that prolonged exposure of mature cystic teratomas to various carcinogens in pelvic cavity may cause malignant transformation. Some authors believe that the long-term presence of MCT and squamous metaplasia of the columnar epithelium may be followed by such malignant change.

The comparison of our study with other studies is shown in Table 3

In our study 5 out of 8 (65%) patients presented in stage I, thus our study supports the idea that malignant transformation arising from MCT presents at earlier stages. Rim et al. reported that eight of 11 patients with malignant transformation were in stage IA. Dos Santos et al. reported 17 cases of SCC arising from MCT, in which stage I-II tumours accounted for 75% of all malignant transformations.

Surgical cyto-reduction along with complete staging and adjuvant treatment as required is the treatment of choice. Prognosis is better when the tumour is completely excised and does not extend beyond the capsule. However, conservative treatment with unilateral salpingo-oophorectomy and surgical staging for early-stage tumours in younger patients

In our study, 6 patients underwent exploratory laparotomy with complete staging. Among these six, one patient had to undergo colostomy as a part of complete staging. One patient received neo-adjuvant chemotherapy followed by interval debulking surgery and adjuvant chemotherapy. One patient in view of advanced disease was given paclitaxel and carboplatin based chemotherapy after histopathological diagnosis by biopsy but she received chemotherapy only as patient denied surgery.

In our series, the median follow-up duration was 36 months. Seven of eight patients survived with no recurrence. In our study, all are alive, doing well, no recurrence and are on regular follow up with us. One patient, advanced stage with skin metastasis (stage IV) expired at home, cause of death remained unknown.

All (100%) patients in present study, with stage I disease have a DFS of more than 3 years, similar to Tseng et al. who reported a 2-year disease-free survival of 100% in four stage IA patients treated with this approach. Peterson et al. showed a 75% 5-year survival rate in cases of unruptured stage I tumours.

Prognosis depends on the extent of the disease, grade of the tumour, and presence of a complete surgical resection similar to epithelial ovarian cancer. One patient who expired had advanced disease with skin metastasis, thus confirming the results of above studies.

Because of the rarity of this tumour, adjuvant treatment has not been prospectively evaluated. According to Sakuma et al.⁽¹⁸⁾ stage IA disease after surgical staging does not require adjuvant chemotherapy. For stage IC and more advanced disease, different adjuvant regimens have been described in individual cases with variable outcomes. For stage IIB-IIIIC disease, Tseng et al. advocated multimodality therapy, including cytoreduction, followed by platinum-based multi-agent chemotherapy with or without pelvic radiation and demonstrated that the overall 2-year disease-free survival was 69%, which is considerably higher than in prior series. All our patients with advanced diseases received carboplatin and paclitaxel based chemotherapy.

In our series, 4 out of eight (50%) patients received chemotherapy, with 3 cycles of paclitaxel 175mg and carboplatin auc 5, 3 weeks apart.

Conclusion:

Preoperative diagnosis of malignant transformation of MCT is very difficult, nearly impossible. There should be high index of suspicion and awareness of the possibility of malignant transformation if the MCT has been present for a long time; the patient is

postmenopausal, age >45 yrs; the tumor diameter is greater than 9.5/9.9 cm; or there is thickening of the cyst wall or papillary growth occurs, increased tumor markers.

A regular examination and follow up through pelvic ultrasonography during the reproductive age may be considered helpful for early detection of the malignant transformation. Further evaluation and long-term follow-up are needed in optimal management of Mt in MCT. At present, early detection and complete resection of all the lesions remain the only reliable treatment methods for this malignancy.

References:

- Peterson WF, Prevost EC, Edmunds FT, et al. Benign cystic teratomas of the ovary; a clinic-statistical study of 1007 cases with review of the literature. *Am J Obstet Gynecol.* 1955;70:368-382.
- Roth LM, Talerman A. Recent advances in the pathology and classification of ovarian germ cell tumors. *Int J Gynecol Pathol.* 2006;25:305-320.
- Ulker V, Numanoglu C, Akbayir O, et al. Malignant transformation arising from mature cystic teratoma of the ovary: A report of six cases. *J Obstet Gynaecol Res.* 2012;38:849-853.
- Bal A, Mohan H, Singh SB, et al. Malignant transformation in mature cystic teratoma of the ovary: report of five cases and review of the literature. *Arch Gynecol Obstet.* 2007;275:179-182.
- Curling ON, Potsides PN, Hudson CN. Malignant change in benign cystic teratoma of ovary. *Br J Obstet Gynecol.* 1979;86:399-402.
- Papadias K, Kairi-Vassilatou E, Kontogiani-Katsaros K, et al. Teratomas of the ovary: a clinico-pathological evaluation of 87 patients from one institution during a 10-year period. *Eur J Gynaecol Oncol.* 2005;26:446-448.
- Kikkawa F, Nawa A, Tamakoshi K, et al. Diagnosis of squamous cell carcinoma arising from mature cystic teratoma of ovary. *Cancer.* 1998;82:2249-2255.
- Wei F, Jiang Z, Yan C. Analysis of 20 mature ovarian cystic teratoma cases in postmenopausal women. *Chin Med J (Engl)* 2001;114:137-138.
- Mori Y, Nishii H, Takabe K, et al. Preoperative diagnosis of malignant transformation arising from mature cystic teratoma of the ovary. *Gynecol Oncol.* 2003;90:338-341.
- Suzuki M, Tamura N, Kobayashi H, et al. Clinical significance of combined use of macrophage colony-stimulating factor and squamous cell carcinoma antigen as a selective diagnostic marker for squamous cell carcinoma arising in mature cystic teratoma of the ovary. *Gynecol Oncol.* 2000;77:405-409.
- Miyazaki K, Tokunaga T, Katabuchi H, et al. Clinical usefulness of serum squamous cell carcinoma antigen for early detection of squamous cell carcinoma arising in mature cystic teratoma of the ovary. *Obstet Gynecol.* 1991;78:562-566.
- Hirakawa T, Tsuneyoshi M, Enjoji M. Squamous cell carcinoma arising in mature cystic teratoma of the ovary. Clinicopathologic and topographic analysis. *Am J Surg Pathol.* 1989;13:397-405.
- Rim SY, Kim SM, Choi HS. Malignant transformation of ovarian mature cystic teratoma. *Int J Gynecol Cancer.* 2006;16:140-144.
- Yoshioka T, Tanak T. Immunohistochemical and molecular studies on malignant transformation in mature cystic teratoma of the ovary. *J Obstet Gynaecol Res.* 1998;24:83-90.
- Ueda G, Fujita M, Ogawa H, et al. Adenocarcinoma in a benign cystic teratoma of the ovary: Report of a case with a long survival period. *Gynecol Oncol.* 1993;48:259-263.
- Dasgupta T, Brasfield R. Metastatic melanoma. A clinicopathological study. *Cancer.* 1964;17:1323-1339.
- Pins MR, Young RH, Daly WJ. Primary squamous cell carcinoma of ovary: report of 37 cases. *Am J Surg Pathol.* 1996;20:823-833.
- Sakuma M, Otsuki T, Yoshinaga K, et al. Malignant transformation arising from mature cystic teratoma of the ovary a retrospective study of 20 cases. *Int J Gynecol Cancer.* 2010;20:766-771.
- Araujo IB, Pinheiro MV, Zanvettor PH, et al. High Frequency of Malignant Transformation of Ovarian Mature Teratoma into Squamous Cell Carcinoma in Young Patients in Northeast Brazil. *Int J Gynecol Pathol.* 2016;35:176-184.
- Oranratanaphan S, Khemapech N. Characteristics and treatment outcomes of patients with malignant transformation arising from mature cystic teratoma of the ovary: experience at a single institution. *Asian Pac J Cancer Prev.* 2013; 14:4693-4697.
- An JS, Wu LY, Li XG, et al. Clinical analysis of 44 cases with malignant transformation of ovarian mature cystic teratoma. *Zhonghua Fu Chan Ke Za Zhi.* 2013;48:123-128.
- Futagami M, Yokoyama Y, Mizukami H, et al. Can malignant transformation in mature cystic teratoma be preoperatively predicted? *Eur J Gynaecol Oncol.* 2012;33:662-665.
- Black JD, Roque DM, Pasternak MC, et al. A series of malignant ovarian cancers arising from within a mature cystic teratoma: a single institution experience. *Int J Gynecol Cancer.* 2015;25:792-797.