

Billiary Intraductal Papillary Neoplasm with Adenocarcinoma

Julie Shah*, Pankaj Modi**, Prujal Parekh***

Abstract

A 20 year old female patient was admitted to the hospital complaints of right hypochondriac pain for 2 years and weight loss. Patients was investigated further with ultrasonography and MRCP which suggested focal sacular dilatation of common bile duct with 50x27x40 mm polypoidal mass within the lumen of common bile duct (CBD). Patient was operated for cholecystectomy and excision of the mass with CBD and Roux-En-Y hepaticojejunostomy. The biopsy of the lesion was suggestive of intraductal papillary neoplasm of bile duct with moderately differentiated adenocarcinoma with intracholecystic papillary tubular neoplasm. Patient developed biliary leak postoperatively which was managed conservatively.

Keywords: Adenocarcinoma, Billiary Intraductal Papillary Neoplasm, Intracholecystic papillary tubular neoplasm, Intraductal mass, MRCP

Introduction:

Intraductal papillary neoplasm of the bile duct (IPNB) is a rare variant of bile duct tumors characterized by papillary growth within the bile duct lumen and is regarded as a biliary counterpart of intraductal papillary mucinous neoplasm of the pancreas. IPNBs display a spectrum of premalignant lesion towards invasive cholangiocarcinoma. The most common radiologic findings for IPNB are bile duct dilatation and intraductal masses. The major treatment of IPNB is surgical resection. Ultrasonography, computed tomography, magnetic resonance image, and cholangiography are usually performed to assess tumor location and extension.

Case Report:

A 20 year old female patient presented in OPD with complaints of chronic, dull aching pain in right hypochondrium since 2 years. Rest of history and physical examination was unremarkable. Her liver function tests within normal limits. Ultrasound abdomen suggested grossly distended gall bladder and

dilated CBD, IHBR, Hepatic and portal venous radicals.

MRCP suggested focal saccular dilatation of CBD with a large (50x27x40 mm) polypoid altered signal intensity heterogeneously enhancing mass within the lumen of dilated proximal CBD. Patient was operated for excision of the dilated CBD segment with polypoidal mass with cholecystectomy and Roux-En-Y hepaticojejunostomy. Mass adherent to portal vein posteriorly was left behind. Biopsy suggested histology of low grade intraductal papillary neoplasm in cystically dilated common bile duct, growth from duct showing histology of moderately differentiated adenocarcinoma – pancreato biliary type and cystic duct and gall bladder showing histology of intracholecystic papillary tubular neoplasm. All resected margin showing infiltration by tumor tissue. TNM stage was T2NxMxG2.

Patient had developed postoperative biliary leak which was managed conservatively.

Discussion:

IPNB is defined as a biliary epithelial tumor with exophytic nature exhibiting papillary mass within the bile duct lumen and with prominent intraductal growth pattern. IPNB can develop anywhere along the biliary

* Resident

** Professor & Head of Unit

*** Assistant Professor, Department of Surgery, B J Medical College, Civil Hospital, Ahmedabad, Gujarat, India

Correspondence : Dr. Pankaj Modi

E-mail : prmodi13@hotmail.com

tree, including both intrahepatic and extrahepatic bile ducts. Mucin hypersecretion and dilatation of the bile duct are sometimes encountered.⁽¹⁾

Formerly, attention has been drawn to biliary tumors with macroscopically visible mucin secretion, which show predominantly papillary growth within the dilated bile duct lumen and secrete a large amount of mucin.⁽²⁾ Since certain morphological features of these tumors, especially intraductal papillary growth pattern, are also similar to those of IPMN of the pancreas, Zen et al.⁽³⁾ proposed that they, together with tumors with macroscopically visible mucin secretion, may belong to a single tumor entity named IPNB. Now, IPNB was adopted in the 2010 World Health Organization (WHO) classification⁽⁴⁾ as a distinct clinical and pathologic entity.

The prevalence of IPNB shows wide geographic variation. The highest incidence is reported in Far Eastern countries, probably because hepatolithiasis and clonorchiasis that are believed to be major risk factors of IPNB are endemic. IPNB is relatively rare and comprises 9–38% of all bile duct carcinomas. Most patients are between 50 and 70 years of age⁽⁵⁾ and show a slight male predominance in most reported series. Intermittent abdominal pain and acute cholangitis or jaundice are the most common clinical manifestations, but certain frequency (5–29%) of patients have no symptoms.⁽⁶⁾ Around 30% of patients have a previous history or concomitant existence of biliary stones.

The most common radiologic findings for IPNB are bile duct dilatation and intraductal masses. The patterns of bile duct dilatation are diffuse duct ectasia, localized duct dilatation, and cystic dilatation, which can be recognized by ultrasonography (US), computed tomography (CT), and magnetic resonance image (MRI). These modalities can also detect intraductal masses, although its sensitivity is reported to be in the range of 41.2–97%.^(7,8) Unlike patients with IPMNs of the pancreas, all patients with IPNB should be considered to treat, because papillary tumours and associated mucin often cause recurrent cholangitis and obstructive jaundice, even if these tumors are not malignant. Patients without distant metastasis are considered for surgical resection.

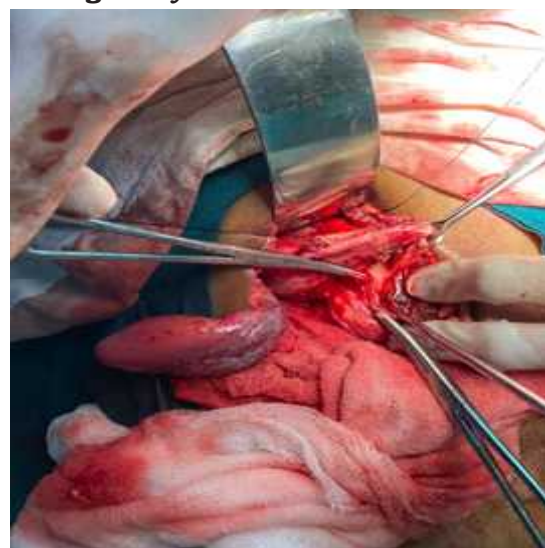
Figure 1: Dissected gall bladder with opened common bile duct

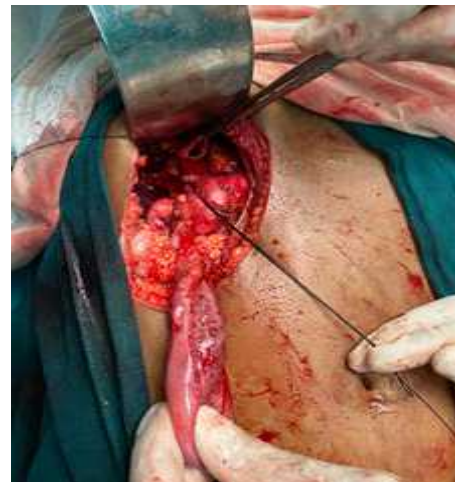

Figure 2 : Specimen containing gall bladder and intraductal papillary growth

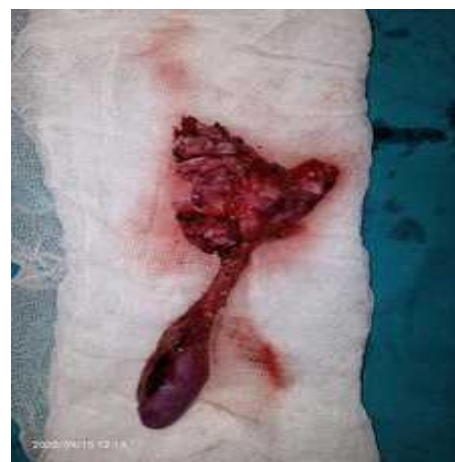

Figure 3: Distal cut end of CBD which appears grossly normal



Conclusion:

Originally, IPNB was proposed as a new disease entity because of striking similarities to IPMN of pancreas, of which the disease entity and clinicopathological features are well established. Unlike patients with IPMNs of the pancreas, all patients with IPNB should be considered to treat, because papillary tumours and associated mucin often cause recurrent cholangitis and obstructive jaundice, even if these tumours are not malignant. Patients without distant metastasis are considered for surgical resection. In order to choose appropriate surgical procedure, exact preoperative assessment of tumour location and extension is important. In particular, for evaluating the extent of superficial spreading, cholangioscopic observation and biopsy is essential. High degree of suspicion should be kept keeping this entity in mind and diagnostic modalities should be used accordingly for preoperative histopathological biopsy to rule out malignancy in IPNB.

References:

1. Blumgart's Textbook of Surgery of the Liver, Biliary Tract, and Pancreas.
2. H. Shibahara, S. Tamada, M. Goto et al., "Prognostic features of mucin-producing bile duct tumors. Two histopathologic categories as counterparts of pancreatic intraductal papillary-mucinous neoplasms," *American Journal of Surgical Pathology*.
3. Y. Zen, T. Fujii, K. Itatsu et al., "Biliary papillary tumors share pathological features with intraductal papillary mucinous neoplasm of the pancreas," *Hepatology*, vol. 44, no. 5, pp. 1333–1343, 2006.
4. Y. Nakanuma, M. Curado, S. Fransceschi et al., "Intrahepatic cholangiocarcinoma," in *WHO Classification of Tumours of the Digestive System*, F. Bosman, F. Carneiro, R. H. Hruban, and N. D. Theise, Eds., pp. 217–227, IARC, Lyon, France, 4th edition, 2010.
5. J. G. Barton, D. A. Barrett, M. A. Maricevich et al., "Intraductal papillary mucinous neoplasm of the biliary tract: a real disease?" *HPB*, vol. 11, no. 8, pp. 684–691, 2009.
6. F. G. Rocha, H. Lee, N. Katabi et al., "Intraductal papillary neoplasm of the bile duct: a biliary equivalent to intraductal papillary mucinous neoplasm of the pancreas?" *Hepatology*, vol. 56, no. 4, pp. 1352–1360, 2012.
7. H. J. Yoon, Y. K. Kim, K. T. Jang et al., "Intraductal papillary neoplasm of the bile ducts: description of MRI and added value of diffusion-weighted MRI," *Abdominal Imaging*, vol. 38, no. 5, pp. 1082–1090, 2013.
8. H. Ogawa, S. Itoh, T. Nagasaka, K. Suzuki, T. Ota, and S. Naganawa, "CT findings of intraductal papillary neoplasm of the bile duct: assessment with multiphase contrast-enhanced examination using multi-detector CT," *Clinical Radiology*, vol. 67, no. 3, pp. 224–231, 2012.