

## Myeloid Sarcoma: Case series and literature review

Mohammed Naseer R\*, Apurva Patel\*\*, Kiran Kumar\*, Mukesh Kumar\*, Harsha Panchal\*\*\*

### Abstract :

Myeloid sarcoma (MS) is a malignant extramedullary tumor consisting of immature cells of myeloid origin. It may precede, present concurrently or follow Acute Myeloid Leukemia (AML) in de novo case or may also be present and might be the only manifestation of recurrent AML, Myelodysplastic syndrome (MDS) or Chronic Myeloid Leukemia (CML). It frequently involves skin, orbit, bone, periosteum, lymph nodes, gastrointestinal tract, soft tissue, central nervous system and testis. Because of its different localization and symptoms, and the lack of diagnostic algorithm, MS is a real diagnostic challenge particularly in patients without initial bone marrow involvement. The correct diagnosis of MS is important for optimum therapy, which is often delayed because of a high misdiagnosis rate. Certain cytogenetic abnormalities are associated with increased risk of extramedullary involvement, potentially through altering tissue-homing pathways. The prognostic significance of extramedullary involvement is not fully understood. Therefore, it has been difficult to define the optimal treatment of patients with MS. Owing to the rarity of this disorder, large series are seldom reported, and the literature is mainly composed of case reports. We at our institute reviewed a series of 5 cases of MS with respect to Clinicopathologic and Immunohistochemical features and compared with available literature.

**Keywords :** Acute Myeloid Leukemia, Cytogenetics, Immunohistochemistry, Myeloid Sarcoma, Myelodysplastic Syndrome

### Introduction :

MS first described in 1853 is synonymously known as Granulocytic Sarcoma (GS), extramedullary myeloid cell Tumour, myeloblastoma.<sup>(1-4)</sup> In adults, the incidence is about 2–5% whereas in children it varies and may reach as high as 40%.<sup>(5)</sup> In adults it is most commonly reported in the skin, bone and lymph nodes,<sup>(6)</sup> whereas in children skin and orbital involvement is more common.<sup>(7)</sup> There are reports of MS presenting after allogeneic stem cell transplantation (allo-SCT).<sup>(8)</sup> We reviewed 5 cases of MS from July 2018 till December 2018 at our institute after Histopathological (HPE) and Immunohistochemistry (IHC) diagnosis and did a literature review.

### Case 1:

A 31-year female evaluated for refractory anemia and thrombocytopenia required multiple transfusion support was referred to our institute. Examination revealed pallor, bilateral axillary ulcerative lesions and hepatosplenomegaly. Biopsy of axillary lesion revealed

MS on HPE & IHC. Imaging found no masses elsewhere in body and there was no involvement of marrow by blasts. This was a de novo MS with an unusual site of presentation and no marrow involvement. Post systemic therapy (7+3-Cytarabine & Daunorubicin), there was resolution of axillary lesions.

### Case 2:

A 33-year male presented with progressively increasing unilateral proptosis. Biopsy of lesion revealed MS on IHC. Patient's further evaluation at our institute suggested bone marrow involvement by blasts with no high-risk cytogenetics. Unilateral proptosis was a masquerader in this case. Post induction with systemic therapy (7+3-Cytarabine & Daunorubicin), there was regression of proptosis with bone marrow remission.

### Case 3:

A 26-year female, who was investigated as a case of periampullary carcinoma was referred to our institute for management. There was pallor, icterus, ascites and hepatosplenomegaly on examination. Work up for Icterus revealed a retroperitoneal nodal mass compressing the bile duct causing Intrahepatic biliary radical (IHBR) dilation. Endoscopic Retrograde Cholangio Pancreaticography (ERCP) with brush

\* Resident

\*\* Professor and Unit Head

\*\*\* Head of Department, Department of Medical Oncology, Gujarat Cancer and Research Institute, Ahmedabad

**Correspondence :** Dr. Apurva Patel

**E-mail :** apurvapatel04@gmail.com

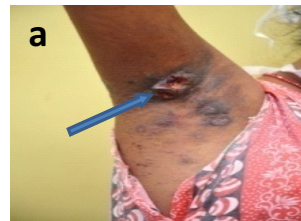cytology and biopsy of nodal mass suggested MS. Further evaluation suggested AML M4 on bone marrow aspiration with positive Inv 16 on cytogenetic analysis. Etiological diagnosis of icterus in this case was a diagnostic challenge. Patient underwent stent placement for dilated IHBR followed by induction chemotherapy (7+3-Cytarabine & Daunorubicin) when bilirubin levels normalized mass compressing the bile duct causing Intrahepatic biliary radical (IHBR) dilation. Endoscopic Retrograde Cholangio Pancreaticography (ERCP) with brush cytology and biopsy of nodal mass suggested MS. Further evaluation suggested AML M4 on bone marrow aspiration with positive Inv 16 on cytogenetic analysis. Etiological diagnosis of icterus in this case was a diagnostic challenge. Patient underwent stent placement for dilated IHBR followed by induction chemotherapy (7+3-Cytarabine & Daunorubicin) when bilirubin levels normalized.

**Case 4:**

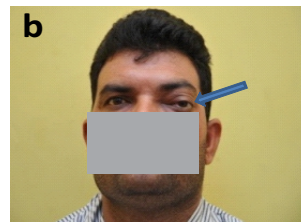A 4-year male, known case of AML M2, good risk (t 8;21 positive) who on surveillance after 3 months post completion of treatment (7+3 Induction and High dose Cytarabine-HIDAC Consolidation) presented bilateral proptosis. Evaluation revealed bilateral superolateral orbital wall infiltration with superior orbital fissure

involvement suggestive of MS on CT Brain & Orbit. There was no marrow involvement by blasts and negative CSF cytology. In view of rapidly progressive orbital lesions we started systemic chemotherapy after literature review as clinical presentation was favoring myeloid sarcoma. There was a very good subjective

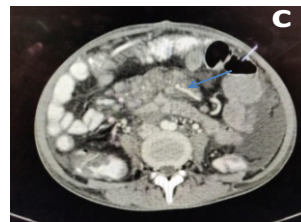
**Photograph 1 : Denovo Myeloid Sarcoma**



a) : Axillary myeloid sarcoma in female



b) : Left eye Myeloid Sarcoma presenting with proptosis



c) : Retroperitoneal MS Biopsy from individual lesions done to confirm diagnosis

**Table 1: Demography and Clinical features**

No.	Age (year)/ Sex	Presentation as Denovo/ Relapse	Presentation	Physical examination	Systemic examination
1	31/F	De novo	Bilateral axillary Mass and refractory anemia and thrombocytopenia	Ulcerative lesion in axillary region; Pallor,	Hepatosplenomegaly
2	33/M	De novo	Left eye Proptosis	Left eye proptosis, Chemosis, Conjunctivitis; Pallor	No Hepatosplenomegaly
3	25/F	De novo	Jaundice, Abdominal distention	Icterus, Pallor, Ascites	Hepatosplenomegaly, Ascites
4	4/M	Relapse	In surveillance for AML, Bilateral Proptosis	Bilateral Proptosis, chemosis and conjunctivitis; Facial palsy	None
5	60/F	Relapse	Scalp nodules	Scalp papular nodules, Pallor	Hepatosplenomegaly

**Table 2: Histopathology, Immunophenotyping, Cytogenetics & Imaging**

No.	BMBx <sup>a</sup>	IPT <sup>b</sup>	Cytogenetics	Imaging	Treatment
1	Hypocellular marrow- No blasts	Degenerated cells	FISH- (8;21) and Inv 16 Negative	USG <sup>c</sup> - Hepatosplenomegaly	Post induction- Healing of axillary lesions
2	AML <sup>d</sup> - M 2 Blasts: 38%	AML Positive for HLAe-DR, Cd13, CD33, CD 117, MPO	FISH <sup>f</sup> - (8;21) and Inv g16 Negative	USG- Hepatosplenomegaly	Post induction- bone marrow under remission
3	AML-M 4; Blasts: 66%	AML Positive for HLA-DR, Cd64, Cd13, CD 117, CD 33, CD 14	FISH (8;21) Negative; Inv 16 Positive in 46%	Ct <sup>g</sup> Abdomen & Pelvis-94x73x120 mm nodal mass involving upper & mid para aortic region. Encasing duodenum, head and uncinate process of pancreas and major abdominal vessels.	Induction death
4	Relapsed AML-M2; Blasts 23%	AML Positive for CD13, CD33, CD117, MPO, CD34, HLADR, CD 13	FISH (8;21) Positive in 75% of cells, Inv 16 Negative	CECT <sup>h</sup> Brain & Orbit-Infiltration in Superolateral wall of bilateral orbit with bilateral extension of superior orbital fissure	Post Clofarabine reinduction bone marrow under remission
5	Relapsed AML-M2; Blasts 56%	Positive for HLA-DR, CD64, CD13, CD 117, CD 33, CD 14	FISH (8.21) and Inversion 16 negative	CECT Brain- Skull vault heterogeneously enhancing areas in frontal skull bone	Post reinduction and Local RT <sup>i</sup> – Mortality due to sepsis

a-Bone Marrow Aspiration (BMBx); b-Immunophenotyping (IPT); c- Ultrasonography (USG);  
d-Acute Myeloid Leukemia (AML); e-Human Leukocyte Antigen (HLA); f- Florescence In situ Hybridization;  
g-Computed Tomography (CT); h-Contrast Enhanced Computed Tomography (CECT); radiotherapy (RT)

response with resolution of orbital swelling. Post clofarabine reinduction, child's marrow is in recovering phase.

#### Case 5:

A 60-year female with no comorbidities with past history of AML M2 presented with isolated medullary relapse after three years of surveillance. She had received conventional treatment regime for Intermediate risk AML (7+3 followed by 3 HIDAC). She was re-induced with 5+2 (Cytarabine & Daunorubicin) when she developed popular lesions over scalp in post induction phase after recovery of marrow. Biopsy of

lesion suggested MS, which had developed after bone marrow relapse in particular with this patient. Local Radiotherapy controlled rapidly progressing MS of scalp, but the patient eventually succumbed to a large intracranial hemorrhage due to low platelet count.

#### Discussion:

Myeloid sarcoma is a rare clinical condition. Pileri et al in a large series of 92 patients reported that 35% of cases occurred concomitantly with AML, 38% of cases had a previous AML history and 27% of cases presented as isolated myeloid sarcoma. In adults with AML, the incidence rate of MS is about 2–5% whereas

In children it varies and may reach as high as 40%.<sup>(1,5)</sup> It may precede, present concurrently or follow Acute Myeloid Leukemia (AML) in de novo case and may also be present and might be the only feature or manifestation of recurrent AML, Myelodysplastic syndrome (MDS) or Chronic Myeloid Leukemia (CML).<sup>(1-4)</sup> At our institute the incidence of Granulocytic sarcoma is 3.08% (5 of 162 cases over 6 months) with 3 females and 2 males. We had only one pediatric patient with myeloid sarcoma, although the incidence of same is higher in children (40%). Majority (80%) presented with concurrent bone marrow involvement with 2 patients (40%) with past history of AML and only one presented with De novo myeloid sarcoma. MS is most commonly reported in the skin, bone and lymph nodes with other sites being body sites being the central nervous system (CNS), oral and nasal mucosa, breast, genitourinary tract, chest wall, pleura, retroperitoneum, gastrointestinal tract and testis.<sup>(7)</sup> In children with newly diagnosed AML, extramedullary involvement is most commonly seen in the skin (54%) with orbital involvement being the second most common site.<sup>(8)</sup> Computerized tomography (CT) and magnetic resonance imaging (MRI) are often used for tumor localization and are helpful in distinguishing MS from other entities, i.e. hemorrhage or abscess.<sup>(9)</sup> With respect to IPT and IHC, the most common markers in our study are HLADR, CD 117. One of our patients had although had good cytogenetic feature t(8;21) relapsed after a disease-free interval of 3 months, the prevalence of same in MS sarcoma in a large study being 9-35%.<sup>(10)</sup> Another patient had with good prognostic cytogenetic Inv 16<sup>(11)</sup> succumbed during induction phase of chemotherapy, the prevalence of which is not known in adults. Falini and colleagues identified NPM1 mutations in 15% of 181 MS patients.<sup>(12)</sup> There is paucity of number of cases with us, no direct conclusions / inferences can be made with respect to treatment of myeloid sarcoma although literature favors institution of systemic therapy for myeloid sarcoma. Despite the rarity of the disease and diagnostic difficulty for clinician, myeloid sarcoma can be correctly diagnosed with strong clinical suspicion and adequate panels of immunohistochemical stains. The bone marrow aspiration, cytogenetic study and molecular analysis are also mandatory for the synchronous AML. Systemic chemotherapy should be administrated shortly once the diagnosis confirmed. A local treatment for myeloid

sarcoma such as radiation therapy or surgical resection has been found less effective than chemotherapy at improving the disease-free interval or disease-free survival. Since its pathogenesis and genomic landscape are not well understood, the prognosis remains dismal, even in the novel agent era. Therefore, each case description is fundamental to provide a better knowledge about this rare malignancy. Further prospective studies are necessary for stratification of the role of chromosome and genetic abnormality and the treatment outcomes.

### References:

1. Klco JM, Welch J, Nguyen T, et al. State of art in myeloid sarcoma. *Int Lab Hem.* 2011; 33:555–65.
2. Bakst RL, Tallman MS, Douer D, Yahalom J. How I treat acute myeloid leukemia. *Blood.* 2011; 118:3785–93.
3. Bain EE, Rothman I, Lin L. De novo myeloid sarcoma in a 4-month-old infant: A case report and review of the literature. *J CutanPathol.* 2013; 40:321–5.
4. Avni B, Koren-Michowitz M. Myeloid sarcoma: current approach and therapeutic options. *Ther Adv Hematol.* 2011; 2:309–16.
5. Ohanian M, Faderl S, Ravandi F, Pemmaraju N, Garcia-Manero G, Cortes J, Estrov Z. Is acute myeloid leukemia a liquid tumor? *Int Cancer.* 2012; 133:534–44.
6. Lan T.-Y, Lin D.-T, Tien H.-F, Yang R.-S, Chen C.-Y, Wu K. (2009) Prognostic factors of treatment outcomes in patients with granulocytic sarcoma. *Acta Haematol* 122: 238-246.
7. Dusenbery K.E, Howells W.B, Arthur D.C, Alonzo T, Lee J.W, Kobrinsky N, et al. (2003) Extramedullary leukemia in children with newly diagnosed acute myeloid leukemia. *J PediatrHematol Oncol* 25: 760–768.
8. Cunningham I. (2006) Extramedullary sites of leukemia relapse after transplant. *Leuk Lymphoma* 47: 1754–1767.
9. Pui M.H, Fletcher B.D, Langston J.W. Granulocytic sarcoma in childhood leukemia: Imaging features. 1994; *Radiology* 190: 698–702.
10. Byrd J.C, Weiss R.B, Arthur D.C, Lawrence D, Baer M.R, Davey F, et al. 1997; Extramedullary leukaemia adversely affects hematologic complete remission rate and overall survival in patients with t(8;21)(q22;q22): Results from cancer and leukaemia group B 8461. *J Clin Oncol* 15: 466–475.
11. Fröhling S, Skelin S, Liebisch C, et al. Comparison of cytogenetic and molecular cytogenetic detection of chromosome abnormalities in 240 consecutive adult patients with acute myeloid leukemia. *J Clin Oncol.* 2002; 20: 2480-2485.
12. Falini B, Lenze D, Hasserjian R, Coupland S, Jaehne D, Soupir C, et al. 2007; Cytoplasmic mutated nucleophosmin (NPM) defines the molecular status of a significant fraction of myeloid sarcomas. *Leukemia* 21: 1566–1570.