

Multiple Osseous Metastases in Malignant Phyllodes Tumor

Muhammed Ali Azher BM*, Shikha Dhal**, Maitrik Mehta***, Ankita Parikh***

Abstract :

Introduction : Phyllodes Tumors (PT) arises from intralobular stroma of breast, accounts for 0.3 to 1% of all primary breast cancers. Only few cases of PT metastatic to bone have been reported so far. **Case report :** A 33 years old female was presented with a 3 month history of pain and swelling of right thigh and functional deformity of right leg. She had a past history of post lumpectomy with metastasis to left iliac bone; histopathology was suggestive of malignant phyllodes tumor (MPT). She had a pathological fracture of her right femur. Later she developed metastases to multiple bones. Palliative irradiation was considered for left iliac bone, right femur and right scapular metastasis. She then received adriamycin and ifosfamide chemotherapy and zoledronic acid. Currently, she has no symptoms and in a stable condition. **Conclusion :** MPT is an aggressive neoplasm of the breast with high rates of local recurrence and distant metastases. The limited role of surgery, chemotherapy and irradiation gives a poor prognosis. The metastases occur in a swift manner and average survival is less than 2 years.

Key Words : Bone Metastasis, Malignant Phyllodes Tumor, Radiotherapy

Introduction :

Phyllodes Tumors (PT) arises from intralobular stroma of breast. PT is a rare breast cancer which accounts for 0.3 to 1% of all primary breast cancers.⁽¹⁾

Although they can occur at any age, most present between the ages of 35 and 55.⁽²⁾ As per WHO, PT is histologically classified as benign, borderline or malignant. The prognosis becomes poor with malignant type with local recurrence in 10-40% and distant metastasis in 10-20%.⁽³⁾ It can present with delayed, distant and isolated bone metastasis even after surgery or chemotherapy.⁽⁴⁾ The metastasis may involve lung (66%), bone (28%) and liver (15%).⁽⁵⁾ Brain Metastases are rare. The five year survival rate of MPT is 66%.⁽³⁾ Metastatic PT carries a more worse prognosis with survival period of less than 2 years.⁽⁶⁾

In our report, we present a case with PT of malignant potential with metastases to multiple bones.

Case Report :

A 33 years old female presented to our institute with history of pain & swelling of right thigh and functional

deformity of right leg since 3 months. Clinical examination revealed single, diffuse, large swelling of 22x24 cm with stony consistency over upper part of right thigh, associated with tenderness and local rise of temperature. Skin over the swelling was tense with engorged veins but not associated with any ulceration or bleeding. Right lower limb movement was grossly impaired.

She had remarkable past surgical history of Lumpectomy on Left Breast in 2013. The histopathological examination of biopsy was suggestive of malignant cystosarcoma phyllodes. She did not receive any adjuvant Radio therapy (RT) and was on irregular follow up after this. On next presentation the following one year, she had developed pain over her left hip. Her bone scan revealed a solitary skeletal metastasis in her left iliac bone. CT guided biopsy of the left iliac bone confirmed metastatic PT. The immuno histochemistry was also conclusive with malignant PT. She received palliative radiotherapy 30Gray/10 fractions at the rate of 3Gray per fraction in November 2014. Following this, she suffered a pathological right trochanteric fracture, associated with a fall. She had surgical fixation of fracture at a local hospital but was lost to follow up, so did not receive palliative radiotherapy. A technetium 99m (Tc99m) labeled 20mci of methylene diphosphonic acid (MDP) bone scan detected new radiotracer uptake in trochanteric region of right femur in June 2015.

* Resident Doctor,

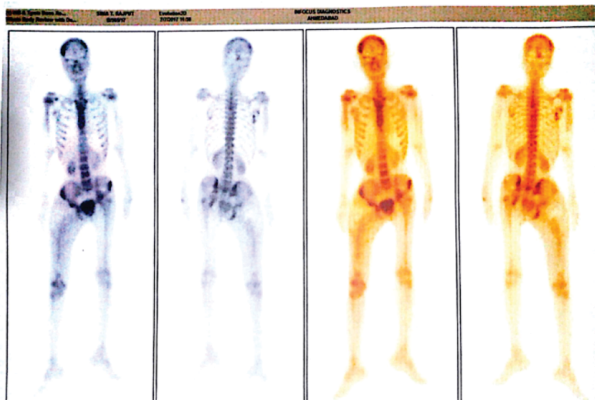
** Assistant Professor,

*** Associate Professor, Department of Radiotherapy, Gujarat Cancer & Research Institute (GCRI), Ahmedabad, Gujarat, India

Correspondence : Dr.Muhammed Ali Azher BM

E-mail : aliazhermuhammed@gmail.com

Figure 1: Bone scan



On her most recent presentation in June 2017 with right limb pain, she had an MRI of the pelvis and bilateral hips which revealed a large permeative ill margined lesion involving head, neck and visualized diaphysis of right femur with cortical erosions with large circumferential extra osseous soft tissue component and marked edema. MRI also suggested metastasis as multiple lesions involving neck and upper diaphysis of left femur, bilateral pelvic bones and sacrum.

She was put on oral morphine 90mg/day for the pain (pain score 9/10 & 10/10). Palliative Radiotherapy was considered at painful site of right femur with its soft tissue mass upto 20Gy/5#. After radiotherapy the pain score came down to 4/10.

During radiotherapy to right femur, she again developed severe pain, swelling of approximate size 2x3cm and deformity over lateral border of right scapula. Trucut biopsy proved it as metastatic PT. She again received palliative radiotherapy to right scapula 30Gy/10#.

In July 2017, Bone Scan revealed new appearance of hot spots at right temporal bone, shaft of right humerus and inferior angle of right scapula along with old lesions of left iliac bone, right femur (Fig. 1).

She received 6 cycles of monochemotherapy of adriamycin and ifosfamide separately along with Zolendronic Acid (ZA). She was kept on monthly ZA.

Discussion :

Only a few cases of PT metastatic to bone reported so far.⁽⁴⁾ The clinical features are non specific and vary with the area of bone involved. Histopathology may show

spindle cells with nuclear atypia and high mitotic index. The ER/PR positive status has never been reported. Metastases occur at different times after primary therapy. Average time is 15 to 26 months after the onset of disease.⁽²⁾ Metastatic disease can present as a solid mass adjacent to involved bone and infiltrate the cortex and medulla in a permeative pattern.⁽⁷⁾ Typical bone scan appearance is of increased Tc99 MDP radiotracer uptake. MRI may better delineate the degree of extension into surrounding tissues which will aid the management strategy.

In addition to palliative radiotherapy, other modalities of local treatment have also been attempted. A case with surgical management is reported by Singer et al. The bony metastasis of proximal right femur was resected and megaprosthesis was placed.⁽⁷⁾

Adriamycin and Ifosfamide have been used as effective agents in the management of metastatic PT.⁽⁸⁾ It can be used as either monotherapy or polytherapy. In our setting, we used single agent Adriamycin first followed by Ifosfamide. Zolendronic acid has demonstrated clinical utility in the treatment of bone metastases.⁽⁹⁾

Conclusion :

Malignant PT is an aggressive neoplasm of breast with high rates of local recurrence and distant metastasis. Metastatic disease arises swiftly and is associated with an average survival of less than 2 years. PT has a poor prognosis, with limited primarily palliative role for surgery, chemotherapy and radiotherapy. Radiotherapy is recommended in recurrent, malignant and metastatic PTs. Specifically, palliative radiotherapy is beneficial for bone and brain metastatic disease.

References :

1. Suzuki -Uematsu S, Shirashi K, Ito T, Adach N, Inage Y, Taeda Y, Uaeki H, Ohtani H, A case report and review of malignant phyllodes tumors with metastasis. *Breast Cancer*, 2010 Jul;17(3):218-224.PMID 193503553.
2. Mitus´ JW, Reinfuss M, Skotnicki P, et al. Population, clinical and microscopic picture, treatment outcomes and prognostic factors in patients with tumor phyllodes of the breast. *Oncol Radiother Med Proj*. 2013;1:45-50. Reinfuss M, Mitus´ J, Duda K, et al. The treatment and prognosis of patients with phyllodes tumor of the breast: an analysis of 170 cases. *Cancer*. 1996;77:910-916.
3. Chaney A, Pollack A, McNeese M, Zagars G, Pisters P, Pollock R, Hunt K: Primary treatment of cystosarcoma phyllodes of the breast. *Cancer* 2000;89:1502-1511.

4. Nguyen B, Imaging of pelvic bone metastasis from malignant Phyllodes breast tumor, Radiology case reports, Vol I, issue 3, 2006.
5. Hlavin ML, Kaminski HJ, Cohen M, Abdul-Karim FW, Ganz E. Central nervous system complications of cystosarcoma phyllodes. *Cancer* 1993;72:126-130.
6. Telli ML, Horst KC, Guardino AE, Dirbas FM, Carlson RW (2007) Phyllodes tumors of the breast: natural history, diagnosis, and treatment. *JNCCN* 5(3):324-330. Reinfuss M, Mitus J, Duda K, Stelmach A, Rys J, Smolak K (1996) The treatment and prognosis of patients with phyllodes tumor of the breast: an analysis of 170 cases. *Cancer* 77(5):910-916.
7. Singer A, Tresley J, Velazquez-Vega J, Yepes M. Unusual aggressive breast cancer: metastatic malignant phyllodes tumor. *Journal of Radiology Case report*. 2013;7:24-37.
8. Asoglu O, Karanlik H, Barbaros U, Yanar H, Kapran Y, Kecer M, et al. Malignant phyllodes tumor metastatic to the duodenum. *World J Gastroenterol*. 2006;12:1649-51.
9. Saad F, Gleason DM, Murray R, et al: A randomized, placebocontrolled trial of zoledronic acid in patients with hormone-refractory metastatic prostate carcinoma. *J Natl Cancer Inst* 94:1458-1468, 2002.