

A Worm in Gall bladder – Victorious or Vanquished? : Diagnostic Dilemma Prevails.....

Afroz Y Bloch*, Neha Patel*, Jaimish Gajjar**, Urvesh Shah***

Abstract :

Parasites in India are a run-of-the-mill phenomenon. Protozoa, sporozoa, cestodes, nematodes and even trematodes – all have discovered a comfortable niche in the Indian soils. Literature spills with cases of all these parasites in varying degrees of their occurrence in the Indian subcontinent. The case being reported here, is out of the aforementioned league. The uncustomary nature of the parasite recovered from the gall bladder of a patient mandates its discussion here. An adult male with jaundice, cholangitis, cholecystitis, gall bladder calculi and, a worm*Ascaris*?, *Fasciola*?,let us unfold the diagnostic dilemma.

Key words : Biliary parasitosis, *Fasciola*, Gall bladder.

Introduction :

Parasitic infections have been endemic in Indian subcontinent owing to the tropical climate & environment. Hepatic & biliary affection by parasites is also a commonplace, & has been reported in several literatures. Among all the parasites, nematodes & hermaphrodite trematodes are the only ones affecting the biliary system.⁽¹⁾ Parasites which may be pathogenic in the biliary tree are *Ascaris lumbricoides*, *Clonorchis sinensis*, *Fasciola hepatica*, *Fasciola gigantica*, *Opisthorchis felinus*, *Opisthorchis viverrini* & *Dicrocoeliasis dendriticum*. These parasites when present in the biliary tree cause a syndrome known as “Oriental cholangiohepatitis”; which is characterized by choledocholithiasis, recurrent cholangitis associated with stone formation, choledochal obstruction. Stone formation is primarily because of the parasite acting as a nidus.⁽²⁾

The clinical symptoms of biliary parasitosis caused by different species are overlapping; ranging from asymptomatic cases, to effects of biliary obstruction, to severe complications like cirrhosis, portal hypertension & cholangiocarcinoma.⁽¹⁾ Diagnosis is based on clinical suspicion due to endemicity of the parasite, radiological investigations like Computed

Tomography(CT) scan, Ultrasonography(USG), Endoscopic Retrograde Cholangio-Pancreatography(ERCP) and; the procurement of adult worm(s) from the biliary tract; or the parasitic ova from either the duodenal aspirate or the faeces. Parasite moving along the biliary tree can also be tracked by radiological investigation as simple as USG. But USG can not track a worm in the duodenum or ampullary orifice; ERCP boasts a considerable say in such cases.⁽³⁾ Hence, a parasite not moving at all within the biliary tract for many days can be already dead in vivo!

In Indian terrains, of the aforementioned parasites, *Ascaris lumbricoides* and *Fasciola spp.* are the commonest.⁽³⁻⁶⁾ So when one isolates an adult worm from the biliary tract or gall bladder; these two are the immediate suspects.

Case report :

A 52 years old male patient was admitted to a tertiary care hospital with complaints of acute & severe right hypochondriac pain associated with vomiting & mild fever since two days. The patient however had a history of ERCP stenting done one month back; when he was admitted with raised Serum Alkaline Phosphatase (ALP), Serum bilirubin, Serum Glutamic Pyruvic Transaminase (SGPT), Serum Glutamic Oxaloacetic Transaminase (SGOT), amylase – all announced obstructive jaundice along with the USG evidences. In April, the patient was investigated & found to have neutrophilic leucocytosis & raised ALP. Bilirubin, SGPT, SGOT were either marginally raised or within the normal range. The patient was again diagnosed

* Assistant Professor,

*** Professor & Head, Department of Microbiology,

** Associate Professor, Department of General Surgery,
GCS Medical College, Ahmedabad

Correspondence : Dr.Afroz Y Bloch

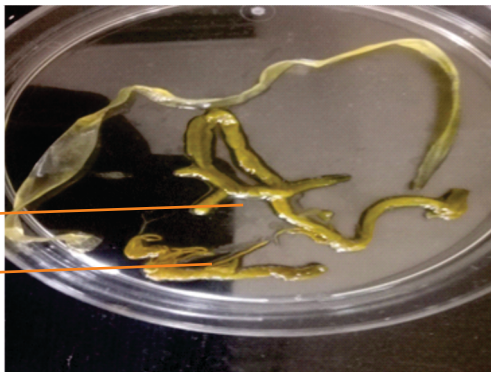
E-mail : dr.roz.saiyed@gmail.com

with obstructive jaundice. Symptomatic treatment, along with intravenous (IV) ceftriaxone was given & stent removal was planned.

Stent was removed after selective Common Bile Duct(CBD) cannulation on 4th day of admission during ERCP. Cholangiogram when taken showed dilated CBD upto lower end with filling defect at distal end. Gall bladder calculi were identified on USG. Sphincteroplasty and stone removal or lithotripsy was advised. Choledochojejunostomy was planned, but postponed due to diarrhoeal episodes of the patient & the patient was discharged.

Patient was admitted again after 20 days for the planned surgery & treated as a case of chronic cholecystitis & obstructive jaundice. Patient was started IV Cefotaxim. Laparoscopic cholecystectomy was done on 6th day of re admission. A yellowish cream colored dead worm, approximately 16 cm long was found per operatively. Adult worm was sent for identification. The retrieved gall bladder was sent for

Figure1(a): Dead adult parasite recovered from the gall bladder.



- (a) bifurcations in the body
- (b) highly branched thread like structures

Figure1(b): Anterior part of the parasite's body.



Figure 2(a) : Parasite's ovum with operculum. (40X magnification, Normal Saline Mount)

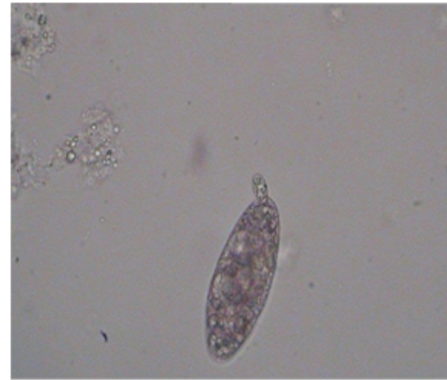
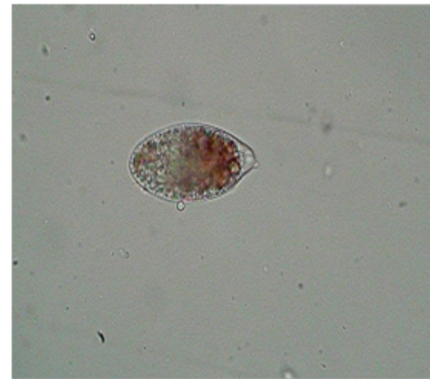


Fig. 2(b): Parasite's ovum with operculum.



histopathological examination, which identified chronic non specific cholecystitis with moderate eosinophilia.

Adult worm was received at the Microbiology laboratory in formalin. The worm was flat ventro-dorsally, with a delineating sheath and dark colored tubular internal structure, which slipped out of the sheath on taking the worm out of the fluid. Morphological characteristics of the worm were assessed(Fig. 1a) : unsegmented flatworm, 16 cm in length, with a thread like internal structure extending from anterior to posterior body, a bifurcation of the internal thread like structure at one end & highly branched thinner thread like structures at the other end. The sheath was hyaline with an anterior oral sucker like structure(Fig.1b). Microscopic examination of the fluid showed occasional ova like structures not resembling any of the common nematodes' ova. The adult parasite was taken in a petridish and a part of its body was teased to squeeze out any ova, if present. This preparation examined microscopically revealed non bile stained, oblong ova with few of them being

Table 1 : Morphometric measurements of the ova*

Sr. No.	Dimensions	Size (µm)
1	Mean length	93.33
2	Maximum length	103.53
3	Minimum length	82.11
4	Mean breadth	38.24
5	Maximum breadth	39.27
6	Minimum breadth	35.7

* The measurements were taken after many days of the worm recovery; possibilities of shrinkage of ova assumed.

Table 2 : Specific features of the recovered parasite and their inferences

Characteristic	Observation	Inference	
Parasites in GB	<i>Fasciola spp.</i>	Common	May be <i>Fasciola spp.</i> or <i>Ascaris lumbricoides</i> .
	<i>Clonorchis spp.</i>	Uncommon in India ⁽⁷⁾	
	<i>Opisthorchis spp.</i>	Uncommon in India	
	<i>Ascaris spp.</i>	Common	
Morphology of adult worm	Length	16 cm	Favours <i>Ascaris lumbricoides</i> .
	Ventro-dorsal thickness & segmentation	Flat & unsegmented	Favours <i>Fasciola spp.</i>
Morphology of ova	Bile staining	Non bile stained	<i>Ascaris & Fasciola</i> , both ruled out?
	Size	103.53µm x 39.27 µm (largest measured)	<i>Ascaris lumbricoides</i> ?
	Operculum	Present	Favours <i>Fasciola spp.</i>

operculated. (Fig. 2a, 2b) The parasite was identified as *Fasciola gigantica*. The treating surgeon gave single dose triclabendazole to the patient; and also started praziquantel & albendazole. The patient was better & discharged with relieved symptoms after 10 days of surgery.

After the worm's identification was documented, confirmation of the diagnosis from two major international authorities in parasitology & fascioliasis was sought. Photographs of the adult worm recovered & the ova identified along with the clinical details of the patient were sent to them. The first of them unexpectedly identified the adult worm as a hyaline structure & the ova as artefacts !!! Hence, for diagnostic assistance, help was pursued from a Professor globally reputed for having unfathomable hold on fascioliasis. A work up to measure the ova's sizes was given to us by him & detailed clinical history of the patient was elicited for the same. The sizes of around 7-8 ova were measured using micrometry. The morphometric measurements of the ova were assessed. (Table 1)

The queries raised by the professor were responded to via e-mail & the photographs of the measured ova were also sent. It was opined by him that the worm isn't *Fasciola spp.* & may be a nematode based on the morphology of the adult worm. The structure of ova however remained paradoxical. The worm unfortunately could not be sent for sequencing as it was preserved in formalin.

Discussion:

As is evident from the case narration, the patient was a clear cut case of biliary parasitosis complicated by cholangitis, obstructive jaundice & gall bladder calculi. The patient also benefitted significantly from the antihelminthic treatment provided after the microbiological diagnosis. The million dollar question however remains – Which was the parasite implicated ?

In quest for the above answer, we sought expert aid as well. The diagnosis given was based on the findings as in Table 2.

As conspicuous from the above table, the diagnosis of the worm's genus was not straightforward. There were

many contradicting & paradoxical findings. Based on the fact, that the adult worm's internal structures & the morphology of the ova, both were uncommonly encountered; the diagnosis was zeroed in on *Fasciola gigantica*. *Fasciola gigantica* are the largest flukes known. It also came to our knowledge that hybrid strains of *Fasciola gigantica* have been encountered; which have unusual morphologies.⁽⁸⁾

The strenuous character of the diagnosis was because of the conflicting & uncomplementing morphologies of the adult worm & its ova. The tie-breaker in this case could have been molecular sequencing; but the preservation of the worm in formalin eliminated its slightest possibility. As formalin is notorious for decreasing DNA solubility & promoting DNA degradation,⁽⁹⁾ such specimens should be stored in alcohol to enable the molecular identification – a very important lesson learnt through this diagnostic drill!

Conclusion:

Certain parasites though uncommon, they do exist. Whenever any rare entity is suspected, one has to go all out for its identification; seeking a recognized expert help early in the process, going through the literature which always adds up to our possibilities of diagnostic work up. The morphometry of the ova could have been complemented by that of the adult worm. But the preservation of the adult worm in formalin, forbidding the molecular sequencing, came out to be the final nail in the coffin of our diagnostic dilemma!

References:

1. Osman M et al: Biliary Parasites. Dig Surg 1998; 15 : 287-96.
2. Yellin AE, Donovan AJ : Biliary lithiasis and helminthiasis. Am J Surg 1981; 142 : 128-36.
3. Das AK : Hepatic and biliary Ascariasis. J Glob Infect Dis. 2014; Apr-Jun; 6(2):65-72.
4. Shetty B, Shetty PK, Sharma P : Ascariasis cholecystitis: An unusual cause. J Minim Access Surg. 2008 Oct-Dec; 4(4): 108-110.
5. Gupta NM : Fasciola gigantica in gall bladder. Indian J Gastroenterol, 1987; 6(2); 113.
6. Ramachandran J, Ajjampur SSR, Chandramohan A, Varghese GM : Cases of human fascioliasis in India : Tip of the iceberg. J of Postgrad Med, 2012; 58(2), 150-2.
7. Bagchi KN : The incidence of Clonorchis infection in India. Ind Med Gaz, 1934 Jun; 69(6): 318-20.
8. Ashrafi K et al : Phenotypic analysis of adults of Fasciola hepatica, Fasciola gigantica and intermediate forms from the endemic region of Gilan, Iran. Parasito Intrnl 2006 Dec; 55(4), 249-60. Srinivasan
9. M, Sedmak D, and Jewell S: Effect of Fixatives and Tissue Processing on the Content and Integrity of Nucleic Acids. Am J Pathol 2002 Dec; 161(6): 1961-71.