

Primary Malignant Melanoma of Breast: Case Report

Jayesh Singh*, Shikha Dhal**, Maitrik Mehta***, Ankita Parikh***

Abstract :

Introduction : Malignant melanoma very rarely involves breast in contrast to skin and mucous membrane. Malignant melanoma of breast can be either primary or metastatic lesion. Primary lesion frequently involves skin and less commonly the glandular parenchyma. We report a case of primary malignant melanoma arose from breast in view of absent primary melanoma lesion elsewhere in body. This case report aims to augment awareness of this rare entity.

Key words : Breast malignancy, Malignant melanoma

Introduction :

Malignant melanoma arises mostly from skin, mucous membrane & other part of body including eye, respiratory, gastrointestinal, genitourinary tract.⁽¹⁾ Rarely they can be found in breast that is <5% of all malignant melanomas.^(2, 3) To diagnose a primary malignant melanoma of breast; clinical examination, histo-pathological features & immunohistochemical staining confirmation is indeed. The comprehensive treatment strategy comprises of primary surgical excision with sentinel lymphnode biopsy or lymphnode dissection of involved nodes followed by adjuvant treatment with chemo-radiation & immunotherapy.⁽⁴⁾

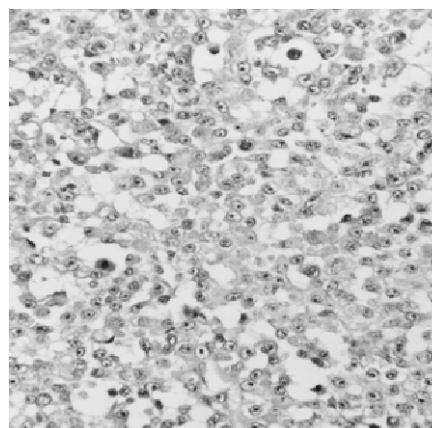
Here we report a case of 45 years old female diagnosed as primary malignant melanoma of breast.

Case report :

A 45 years old female presented with lump in right breast for two months. She had no previous history or family history of any malignancy. Clinical examination revealed 3X3cm sized mass in upper quadrant of right breast in vicinity of the nipple areola complex without local skin color change, discharge from or retraction of the nipple. No other mass or lesion was seen in other parts of body. There was no lymphadenopathy in both axilla, supraclavicular region and neck. Mammography of both breast suggestive of few ill-defined hypoechoic lesions in upper quadrant and retro-areolar region of right breast (largest 33x22mm); possibility of

multi-centric mass lesion or malignant mass lesion with satellite nodules (largest 5x4mm) BIRAD V. Fine needle aspiration biopsy was done which came to be negative for malignancy. Patient underwent right breast lumpectomy, histopathology was indicative of high grade malignant tumor; possibility of invasive ductal carcinoma not otherwise specific type [figure 1].

Figure 1: High grade malignant tumor 40x



In immunohistochemistry, AE1, ER, PR, HER-2-neu, LCA, CD20 were negative. A comprehensive routine & metastatic workup was done including contrast enhanced computed tomography of thorax, ultrasonography of abdomen and pelvis ruling out any metastasis. Later modified radical mastectomy with axillary lymphnode dissection of right breast was done, with histopathological examination was suggestive of high grade malignant tumor of sized 6x5x1.5cm with lympho-vascular permeation by tumor cells; nipple areola complex, base of resection & surgical margins were free from tumor cells and one out of six lymphnode was positive for malignant cells without peri-nodal extension. Immunohistochemistry

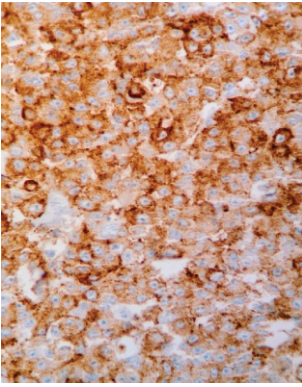
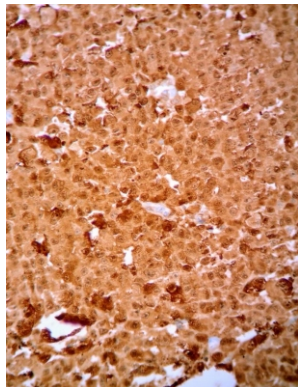
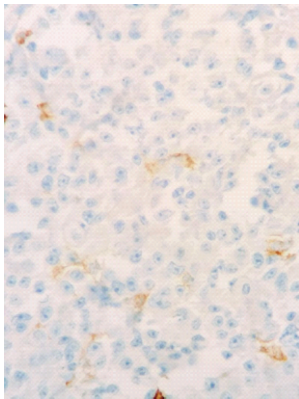
* Resident

** Assistant Professor

*** Associate Professor, Department of Radiotherapy,
Gujarat Cancer Research Institute, Ahmedabad, Gujarat, India

Correspondence to : Dr. Jayesh Singh,

e-mail: dr.singh3788@gmail.com

Figure 2: HMB 45 +**Figure 3: s100 +****Figure 4: LCA -**

demonstrated that tumor cells were positive for HMB45, S-100, vimentin and negative for cytokeratin, estrogen receptor, progesterone receptor, HER2neu, LCA, CD20, CD30, EMA, Desmin, CK7 which rules out invasive ductal carcinoma, lymphoma and sarcoma [figure 2, 3, 4].

On basis of immunohistochemistry, malignant melanoma of right breast diagnosis was suggested. After taking meticulous history, we found that she had a small mole over right breast in upper quadrant 25 years ago which was excised by local private practitioner but no documentary proof was available regarding its nature.

Discussion :

Malignant melanoma arises from melanocyte, a melanin producing neural crest derived cells. Incidence has risen over last decade. It most commonly involves extremities and trunk in females & males respectively.⁽⁵⁾ Though etiology of the tumor is unknown, it is seen to be associated with exposure to ultraviolet radiation in

addition to family history, multiple moles and poor immune function.⁽⁶⁾ Malignant melanoma arises mostly from skin, mucous membrane & other part of body including eye, respiratory, gastrointestinal, genitourinary tract but rarely occur in breast, <5% of all malignant melanomas.^(1, 2, 3) It can be primary melanoma of breast skin or glandular parenchyma and metastasis to breast from other primary malignant melanoma site in the body. Diagnosis of primary malignant melanoma of breast is based on clinical examination, histopathological features and immunohistochemical staining confirmation. Individual melanoma cells are usually considerably larger than nevus cells. They contain large nuclei with irregular contours having chromatin characteristically clumped at the periphery of the nuclear membrane and prominent eosinophilic nucleoli giving a "cherry red" appearance.⁽⁷⁾ Melanoma cells are immunohisto-chemical positive for HMB-45, S-100, Melan-A.⁽⁸⁾

Upfront surgical resection with adjuvant chemotherapy and immunotherapy are considered the probable treatment strategies. Wide local excision is the surgical approach of choice along with sentinel lymphnode biopsy or nodal dissection of tumor draining lymphnode sites. Our case was misled with negative biopsy and lumpectomy diagnosis of invasive ductal carcinoma, so completion modified radical mastectomy was performed to ascertain the diagnosis. A study by Papachristou et al showed that melanotic lesion located 3cm below the clavicle metastasized to axillary lymphnodes and lesion located 3cm above the clavicle involved cervical region lymphnodes.⁽⁹⁾ Indication of post-operative radiotherapy includes unresectable mass, margin positive, local recurrence, multiple lymphnode positive (4 or more), large lymphnode (>3cm).^(4, 10) Our patient underwent post-operative radiotherapy in view of inadequate lymphnode dissection up to a dose of 45gy in 20 fractions, 5 fractions a week as per institutional protocol. Immunotherapy with interferon-2b has role in adjuvant therapy of malignant melanoma.⁽¹¹⁾

Conclusion :

Primary malignant melanoma of breast is a rare tumor. It be confused with high grade ductal carcinoma (grade 3) based on histology alone. Immunohistochemistry can

confirm the diagnosis. Early diagnosis, correct surgical approach and comprehensive adjuvant therapy has a pivotal role in improving patient's survival.

References :

1. Edward C, David E, Carlos A, Luther W. Perez and Brady's principle and practice of radiation oncology, 6th edition; vol2;section III (33)-627
2. Kurul S, Tas F, Buyukbabani N, Mudun A, BaykalC, Camlica H. Different manifestations of malignant melanoma in the breast: a report of 12 cases and review of literature. *Jpn J ClinOncol.* 2005;35:202-6.
3. Alzaraa A, Sharma N et al. Primary cutaneous melanoma of the breast: a case report. *Cases J.* 2008;1:212.
4. He Y, Mou J, Luo D, Gao B, Wen Y. Primary malignant melanoma of the breast: A case report and review of the literature. *Oncol Lett* 2014;8:238-40.
5. Balch CM, Gershenwald JE, Atkins MB, Buzaid AC, Cascinelli N, Cochran AJ, et al. Melanoma of the skin. In: Edge SB, Byrd DR, Compton CC, Fritz AG, Greene FL, Trotti A, editors. *AJCC cancer staging manual.* 7th ed. New York: Springer; 2010. pp. 325–344.
6. English DR, Armstrong BK, Krickler A, Fleming C. Sunlight and cancer. *Cancer Causes Control.* 1997;8:271–283.
7. Robbin's basic pathology; 8th edition; 22;857.
8. Bonetti F, Pea M, Martignoni G, Mombello A, Colombari R, Zamboni G, et al. False-positive immunostaining of normal epithelia and carcinomas with ascites fluid preparations of antimelanoma monoclonal antibody HMB45. *Am J ClinPathol*1991;95:454-9.
9. Papachristou DN, Kinne DW, Rosen PP, Ashikari R, Fortner JG. Cutaneous melanoma of the breast. *Surgery.* 1979;85:322–328.
10. Bhagyalakshmi A, Uma P, Satya Sri S, Kumar SV. Malignant melanoma of breast: A case report. *Int J Res Med Sci* 2014;2: 755-8.
11. Davar D, Tarhini AA, Kirkwood JM. Adjuvant therapy for melanoma. *Cancer J.* 2012;18(2):192-202.