

Role of Computed Tomography Scan in Buccal mucosa Cancer

Nikunj C Desai,* Swati S Shah,** Zalak Patel***

Abstract :

Introduction : The most common type of buccal mucosa tumor is squamous cell carcinoma. In the tumours of the tongue, floor of mouth & oropharynx the imaging to localize the size & extent of primary tumour is critical for planning of surgery & radiotherapy. Thus, it is helpful to ensure adequate resection of tumour margin, to determine radiotherapy field & over all to improve patient's prognosis. **Materials & Methods:** Total 50 such patients were referred to Radiology Department at tertiary care institute, Ahmedabad (western India). They were subjected for CT scan examination on 16 slice CT scanner. CT scan evaluation was made for size and extent of primary mass lesion. The staging of disease was performed with TNM classification. **Result & Conclusion:** In our study, CT proved to be highly reliable at 98% in detecting bone erosion. However, accuracy of 60% was seen for N0 stage nodal involvement. Hence the role of CT in diagnosis of buccal mucosa cancer as well as to know its spread is immense.

Key words : Buccal mucosa, Cancer staging, CT scan

Introduction :

Buccal mucosa cancer is the commonest form of cancer in India particularly in male community with the habit of tobacco chewing. Though the cancer can be visualized directly on clinical examination, its deeper extension is difficult to evaluate. Hence, the role of Computed Tomography (CT) in diagnosis of buccal mucosa cancer as well as to know its spread is of immense significance. Higher incidence of Squamous cell cancers (more than 90%) of gingivobuccal mucosa in India is due to high rate of tobacco chewing. Hence it is also referred to as Indian oral cancer. ⁽¹⁾ In fact, it accounts for roughly 30-35% amongst all the cancers.

With the advent of Computed Tomography (CT), the staging of buccal mucosa tumours has become more accurate, leading to proper treatment planning and execution. We hereby present our experience with CT examination of buccal mucosa tumours and wish to demonstrate the technique and approach to its diagnosis and staging.

Materials & Methods :

Total 50 suspected patients of oral cancers were referred to Radiology Department at tertiary care

institute, Ahmedabad (western India). They were subjected for CT scan examination on 16 slice CT scanner. Imaging was performed from paranasal sinus and neck region with axial sections from skull base to clavicles, after injection of intravenous iodinated contrast media. Multiplanar sagittal and coronal reformation images were obtained using Multi Planar Imaging (MIP) and 3D reconstruction algorithm. Puffed cheek manoeuvre was performed to separate gingival and oral buccal mucosa in all the cases for improved detailed evaluation. ⁽²⁾

CT scan evaluation was made for size and extent of primary mass lesion. Disease was considered to be advanced based on CT criteria like bone erosion, skin infiltration, buccal space infiltration and extension to retro molar trigone. Nodes were evaluated for size, enhancement and presence of necrosis. Radiological findings were correlated with clino-pathological findings of the lesion. Statistical analysis of data obtained was made in terms of demographics of the subject and disease staging was performed with TNM classification as per American Joint Committee on Cancer (7th edition).

TNM staging for Squamous Cell Carcinoma in oral cavity and lips:

Tumor

- TX - Primary tumor cannot be assessed
- T0 - No evidence of primary tumour
- Tis - Carcinoma in situ

* Assistant Professor,

** Professor,

*** Ex- Assistant Professor, Department of Radiodiagnosis,
GCS Medical College Hospital & Research Centre,
Ahmedabad, Gujarat, India

Correspondence to : desainikunj65@gmail.com

- T1 - Tumor size less than or equal to 2 cm
- T2 - Tumor size 2-4 cm
- T3 - Tumor size > 4cm
- T4a - Oral Cavity Tumor invades through cortical bone, into deep [extrinsic] muscle of tongue (genioglossus, hyoglossus, palatoglossus, and styloglossus), maxillary sinus, or skin of face
- T4b - Tumor involves masticator space, pterygoid plates, or skull base and/or encases internal carotid artery. Superficial erosion alone of bone/tooth socket by gingival primary is not sufficient to classify as T4.

Node

- Nx Regional lymph nodes cannot be assessed
- N0 No regional lymph node metastasis
- N1 Metastasis in a single ipsilateral lymph node, 3 cm or less in greatest dimension
- N2 Metastasis in ipsilateral or contralateral node or nodes less than 6cm in greatest dimension
- N2a Metastasis in a single ipsilateral lymph node – 3-6cm in greatest dimension
- N2b Metastasis in multiple ipsilateral lymph nodes, none more than 6 cm in greatest dimension
- N2c Metastasis in bilateral or contralateral lymph nodes, none more than 6 cm in greatest dimension
- N3 Metastasis in a lymph node more than 6 cm in greatest dimension

Staging Criteria for Buccal Mucosal Malignancy: ⁽³⁾

Stage	TNM staging	Criteria
I	T1N0M0	Tumour < 2cm
II	T2N0M0	2cm > tumour < 4cm
III	T3N0M0 or T1/T2/ T3 - N1M0	Tumour > 4cm OR ipsilateral node < 3cm
IV	T4N0M0 or T1/T2/T3- N2/N3M0 or M1	Invasive lesions infiltrating skin and eroding bone All N2 N3 lesions -bilateral or multiple ipsilateral nodes All M1 lesions -distant metastases

Metastases

- Mx - Distant metastasis cannot be assessed
- M0- No distant metastasis
- M1 - Distant metastasis

Results:

Out of total 50 patients, highest incidence of buccal mucosa malignancy was encountered in 4th decade (44%) followed by 3rd decade (22%). However, we also encountered 2 cases in early 2nd decade (Table-1). Majority of the patients encountered were males (92%), as compared to female population at a meagre 8%. This was related to a higher incidence of tobacco chewing in males.

Table 1: Age wise distribution of patients

Age Group (years)	No. of patients (%)
20-30	2 (4%)
31-40	11 (22%)
41-50	22 (44%)
51-60	9 (18%)
61-70	6 (12%)

Table 2: TNM stage wise distribution of tumour

T stage						
T stage	T1	T2	T3	T4a	T4b	
No. of patients	6	9	4	20	11	
N stage						
N stage	N0	N1	N2a	N2b	N2c	N3
No. of patients	05	09	00	26	04	02
M stage						
M stage	M0			M1		
No. of patients	50			0		
Over all staging						
Stage	I	II	III	IV		
No. of patients	5	3	3	39		

Majority of the patients had advanced disease; 62% were having T4 stage and 78 % were having stage IV. The lesions were staged as T4a mainly due to criteria of local skin invasion and alveolar bone erosion. 10 cases were classified as T4b stage with extension to masticator space below the mandibular notch, while 1 patient showed involvement of infra-temporal fossa. Only 5 patients in this study had stage I disease which was more of a clinical diagnosis. CT scan could not give any added information in these cases. 52% of patients showed N2b nodal involvement i.e. single or multiple ipsilateral or bilateral nodes less than 6cm in size.

Discussion:

Oral cavity tumours are ranked number one cancer in Indian population with 2:1 (male: female) sex preponderance.⁽⁴⁾ The incidence of buccal mucosa tumour in male is twice as compare to female population in the study by R. Sankaranarayanan et al.⁽⁴⁾ However, in our study we encountered 92% of male population compared to only 8% of female population with 11.5: 1 (male: female) sex preponderance.

CT and MRI are complementary to each other. However CT scan is considered to be the modality of choice due to easy availability and faster image acquisition than MRI. MRI also is a good modality to detect oral cancers due to its high contrast resolution. CT demonstrates cortical bone erosion better than MRI^(5,6) while MR can show marrow involvement, neural involvement better than CT. Spread of tumour; nodal involvement and bone erosion can be detected accurately on CT. For accuracy of reporting, sound anatomical knowledge of oral cavity is mandatory.

CT Anatomy of Buccal mucosa

CT being readily available and a faster technique, serves as modality of choice for assessment of buccal mucosa lesions. Techniques like puffed cheek manoeuvre and oblique scans to prevent dental amalgam artefacts have further helped in enhanced view of the lesions. CT provides better assessment of cortical bone erosion.

To understand the pathology, it is very essential to know the CT anatomy of buccal mucosa and to understand the path of spread of the malignant lesion.⁽⁷⁾

Oral cavity includes the anterior two thirds of the tongue, the floor of the mouth, the mandibular alveolus, the maxillary alveolus, the hard palate, the lips, and the cheeks (bucco-masseteric region).⁽⁸⁾ Buccal mucosa is lined along upper and lower alveolus. Gingivo-oral mucosa is along the alveolar bony margins and gingivo-buccal mucosa is along the buccal mucosal surface.

These are distinguishably seen on puff cheek manoeuvre. Alveolar canal is seen in ramus of mandible and comprises of neurovascular bundles.

Lateral to buccal mucosa lies buccal fat space, bounded by zygomaticus major muscle laterally and buccinator muscle medially. It consists of the buccal fat, facial artery and vein, buccal artery and nerves (not identified on imaging), the terminal part of the parotid duct and the facial node. Superiorly this space leads to the masticator space with often incomplete fascial boundaries between.⁽⁹⁾ Posteriorly, buccal mucosa is continuous with retromolar trigone. Retromolar trigone is triangular space bounded by last mandibular molar tooth anteriorly and anterior surface of lower ascending ramus of mandible posteriorly. It lies at crossroads and is gateway to passage of disease to oral cavity, parapharyngeal space, infratemporal fossa and buccal fat space. On CT images, the retromolar trigone is seen in consecutive axial sections, the upper limit behind the maxillary last molar & the lower limit behind the mandibular last molar.

CT staging of buccal mucosa tumours

To stage the disease precisely, it is very important to understand the route of spread of buccal mucosa cancers.

Pattern of spread of buccal mucosal tumour

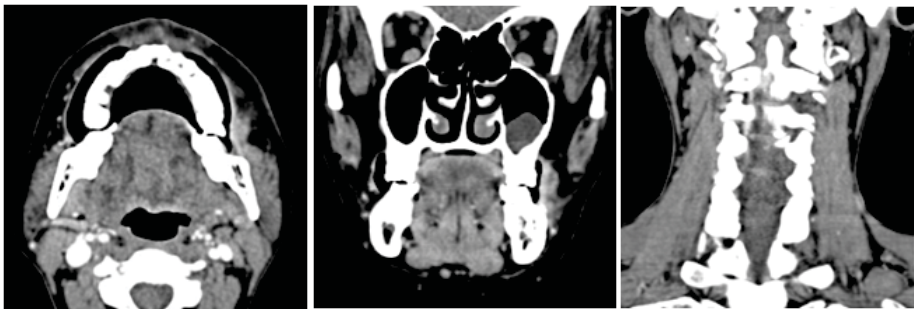
Buccal mucosa cancer can spread from gingivobuccal mucosa to buccal fat space and to overlying skin. From gingivooral mucosa, the lesion may cause erosion of bony alveolus and extend into floor of mouth. Posteriorly, the lesion may extend to retromolar trigone, masticator space, while superiorly it may extend into infratemporal fossa.

The lesion in retromolar trigone may extend to oral cavity in tonsillar region. It can cause erosion of mandibular alveolus and may show perineural extension through alveolar canal. The lesion may erode pterygoid plates and may extend to pterygoid fossa and infratemporal fossa. Lesion in central arch region may extend along gingivolabial mucosa to involve lips or may infiltrate anterior floor of mouth.

Nodal spread of buccal mucosa tumour

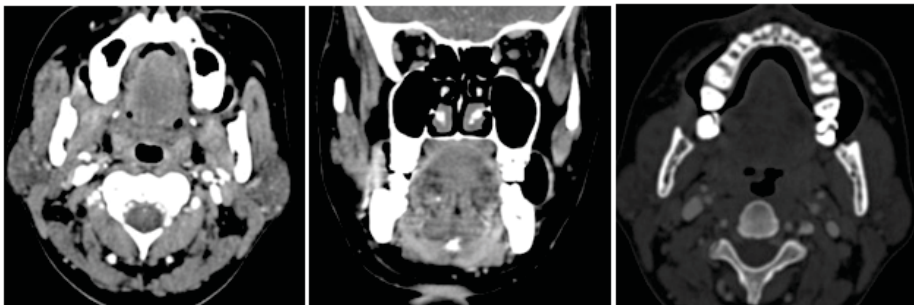The oral mucosal space drains to bilateral submental and submandibular lymph nodes. The criteria for nodal involvement assessment were enlargement, enhancement and necrosis within the nodes. However, even subcentimeter nodes at primary drainage site should be considered suspicious of malignancy.

Figure 1 : Patient with stage I malignancy showing 1.8cm sized lesion with no nodal involvement, bone erosion or intraoral extension.



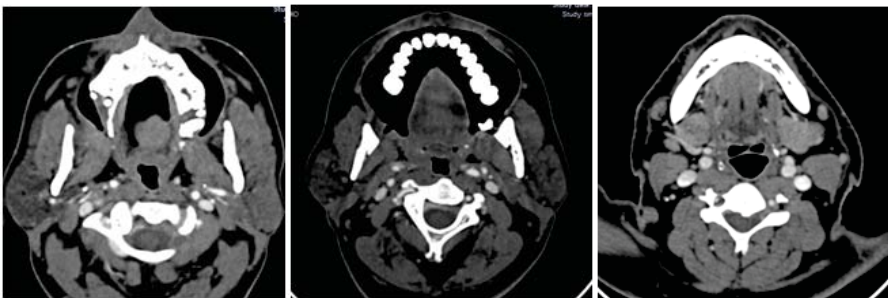Stage I tumour shows buccal mucosal lesion less than 2 cm in size with no bone erosion or neck lymphadenopathy (Fig 1).

Figure 2 : Stage II malignancy showing mass in retro molar trigone 3cm in size with no nodal involvement or bony erosion.



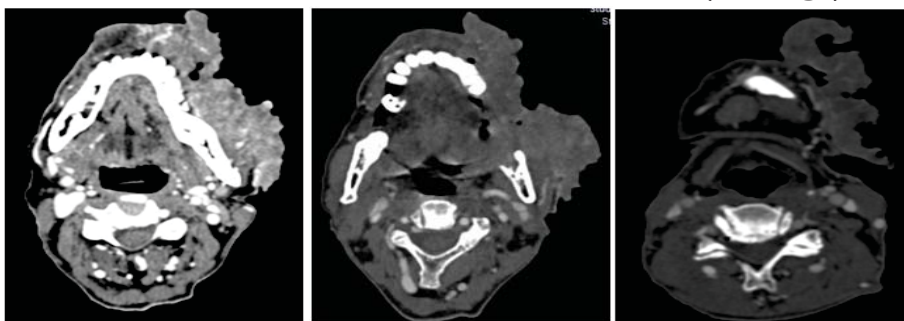
Stage II tumour shows tumour more than 2cm and less than 3cm with no bone erosion or neck lymphadenopathy (Fig 2)

Figure 3 : Patient with stage III malignancy showing en plaque lesion eroding upper bony alveolus without nodal involvement.



Stage III tumor shows upper alveolar mucosa lesion eroding upper bony alveolus without nodal involvement (Fig 3).

Figure 4 : Patient with stage IV malignancy showing large ulcerated mass infiltrating left buccal fat space, and overlying skin, extending to retromolar trigone, causing bone erosion with intraoral extension (T4 stage)



Stage IV tumour shows lesion invading overlying skin, causing bone erosion and extends into Infratemporal fossa, pterygopalatine fossa (Fig 4).

As per study by Leslie et al CT imaging has 67% of accuracy for staging of primary buccal mucosa tumors while for detecting recurrent tumour it has 100% accuracy, which is more than MRI. ⁽¹⁰⁾ In our study, CT proved to be highly reliable at 98% in detecting bone erosion which was confirmed by surgery. However, accuracy of 60% was seen for N0 stage nodal involvement. Out of 5 cases with N0 stage disease, 2 showed positive nodes on surgery.

Evaluation for skin invasion, bone erosion, retromolar trigone, infratemporal fossa and pterygopalatine fossa involvement formed integral part of assessment for staging of buccal mucosa masses. CT staging of tumours had direct impact on treatment of the lesions. The lesions were considered to be resectable up to T4a stage disease.

Conclusion :

Buccal mucosa cancers are alarmingly increasing in younger population due to tobacco usage (26 % being reported in < 40 years of age in present study). CT plays a very important role in staging of buccal mucosa malignancy and effectively detects bone erosion (98 % sensitive) and invasion to infratemporal fossa. Treatment planning and execution very much depends on CT staging of the disease. However, CT scan may not be much useful during early stage of malignancy.

References :

1. S.Tibrewala, S. Roplekar, R. Varma , Computed Tomography Evaluation of Oral Cavity and Oropharyngeal Cancers. *Int. J. OtorhinolaryngolClinic* 2013;5⁽²⁾: 51-62
2. L.Jane, Weissmanaand L. Richard, Carraua, Puffed-cheek” CT Improves Evaluation of the Oral Cavity.*AJNR*2001 22: 741-744
3. Edge SB , Compton CC.; *Ann Surg Oncol.* 2010 Jun;17⁽⁶⁾:1471-4. The American Joint Committee on Cancer: the 7th edition of the AJCC cancer staging manual and the future of TNM.
4. R. Sankaranarayanan. Oral cancer in India: An epidemiologic and clinical review. *Oral Surgery, Oral Medicine, Oral Pathology-* March 1990; Volume 69, Issue 3: 325–330
5. Stambuk HE, Karimi S, Lee N, Patel SG. Oral cavity and oropharynx tumours. *Radiol Clin N Am*2007;45:1–20 [PubMed]
6. Mukherji SK, Isaacs DL, Creager A, Shockley W, Weissler M, Armao D. CT detection of mandibular invasion by squamous cell carcinoma of the oral cavity. *AJR Am J Roentgenol* 2001;177:237–43 [PubMed]
7. C. P. Law, R. V. Chandra, J. K. Hoang, and P. M. Phal, Imaging the oral cavity: Key Concepts for the Radiologist : *The British Journal of Radiology* 2011 84:1006, 944-957
8. WRK.Smoker,Oral cavity. In: SomPM, Curtin HD, eds. *Head and Neck Imaging.* 3rd ed. St Louis: Mosby-Year Book 1996; 488-544
9. S.Arya, D.Chaukar, P.Pai , Imaging in oral cancers. *Indian Journal of Radiology and imaging* 2012; 22:195
10. Leslie, Anna; Fyfe, Ethyne; Guest, Phil; Goddard, Paul; Kabala, Julian E. Staging of Squamous Cell Carcinoma of the Oral Cavity and Oropharynx- A Comparison of MRI and CT in T- and N-Staging. *Journal of Computer Assisted Tomography:* January/February 1999 - Volume 23 - Issue 1 - pp 43-49