

Pectoralis Major Myocutaneous Flap in Head and Neck Reconstruction : An Experience in 100 Consecutive Cases

Gunjan H Shah*, Mitul Mistry**, Jolly Pandit**

Abstract:

Introduction : Reconstruction following head and neck surgery is a challenging task. Face and neck are identity of individual. That is very important to restore form and function of appearance, speech, swallowing. In this paper we have analyzed these aspects following soft tissue reconstruction in respect to reliability of flap versus restoration of form and function. **Materials and Methods :** We retrospectively analyzed 100 Pectoralis Major Myocutaneous flap (PMMC) flaps from 2011 to 2016 performed at GCS Medical College and Hospital, Ahmedabad. The totals of 100 (n=100) PMMC flap reconstructions were performed. Out of 100 15 patients were in stage I and II, 18 patients were in stage III, and 67 patients were classified in stage IV. Patients were also divided as per primary subsites. **Results :** A total of 100 patients were reviewed for study. Most tumors were advanced (T3 or T4a) lesion. 98 reconstructions were done as a primary procedure, and 2 were salvage procedure. PMMC flap was used to cover only mucosal defect in 84 patients, skin and mucosal in 16 patients. Flap related complications were classified. None of the patients had total flap necrosis. 28 patients had infections which resolved by conservative management. Minor complications and donor site complications included fistulas that were managed conservatively; wound dehiscence not requiring additional surgery, local infections, seromas, and hematomas. **Conclusion :** PMMC flap is a versatile flap with excellent reach to the oral cavity and face and neck region. With limited expertise and resources it is still a primary choice and workhorse flap in head and neck reconstruction.

Key words : Reconstruction, Head and Neck Surgery, PMMC flap

Introduction:

Reconstruction following head and neck radical surgery is a challenging task. Even though microvascular free flaps are considered as gold standard that requires resources and training and strict post-operative care. ⁽¹⁾ popularity of microvascular flaps are increasing due to their availability of complex and composite tissue transfer i.e., bone, muscle, nerve, skin, mucosa; and even the range of tissue availability is also more Reliability, versatility, and ease of harvest have been the hallmarks of the PMMC flap. Established uses include esophageal luminal augmentation, reconstruction of oral cavity and oropharyngeal defects, lateral mandibular defects, skull base and temporal bone defects, orbitomaxillary defects, and cutaneous defects of the cheek, neck, and chin. ⁽²⁾ Due to easy learning curve and robust vascularity PMMC flap is workhorse at many centers. ⁽³⁾ PMMC flap may be used most of the times with segmental defects of mandible either with or without disarticulation. The use may also be done with intact mandible or with marginal

mandibulectomies. The first use of PMMC was described in 1947 for cardiothoracic defects. It is still an unmatched option even after 40 yrs of its description by Arian et al. ⁽⁴⁻⁸⁾ especially in patients with advanced head neck malignancy this holds principle mode of reconstruction. At our center head and neck malignancy constitute a major disease bulk in adult population with most patients reporting in advanced stages. PMMC flap is a principle mode of reconstruction following composite resections. It provides bulk for a composite defect with acceptable cosmetic outcomes. We present a retrospective analysis of 100 patients with PMMC reconstruction from year 2011 to 2016. ⁽⁹⁾

Materials and Methods :

We retrospectively analyzed patients who have undergone resective surgery for head neck cancer and reconstructed with PMMC flap. All patients were operated at GCS medical college and hospital from 2011 to 2015. All patients were subjected to routine investigations for general anesthesia. Informed consent was taken from all patients for future necessity for scientific research. Out of all patients that were operated; 100 patient's follow-up data could be traced. Total 100 patients who underwent PMMC

* Assistant Professor,

** Tutor, Department Of Faciomaxillary Surgery and Dentistry, GCS Medical College, Hospital & Research Centre, Ahmedabad, Gujarat, India

Correspondence : ghs_48@yahoo.com

reconstruction were incorporated in the study (n=100). Data were analyzed with regard to clinical representation, tumor stage, size, primary site, nodal status, operative procedure and postoperative complication rates. Ipsilateral PMMC flap was used for reconstruction in 98 patients, in 2 patients contra lateral PMMC was harvested.

Technique of harvesting PMMC

The surface marking of the vascular pedicle were made by drawing a line from the ipsilateral acromion to the xiphisternum and other line vertically from the midpoint of clavicle to intersect first line perpendicularly. The skin paddle was designed so that it comes along course of pectoral or descending branch of thoracoacromial artery.

During the elevation the care is taken not to undercut the skin paddle but rather to bevel it, so as to include as many perforators as possible. The skin paddle was suture to the underlying pectoralis muscle to minimize the risk of shearing injury to myocutaneous perforators. The plane of dissection between pectoralis minor and major muscle with its vascular pedicle was found by dissecting the lateral border of pectoralis major muscle. Once in the plane we could easily free the pectoralis major, with its vascular pedicle from the pectoralis minor muscle. The pectoralis major muscle was divided lateral to the pedicle while keeping the pedicle in view, thereby freeing it from the humerus. A portion of clavicular fibers was divided to include only neurovascular pedicle and its adventitia, eliminating the supraclavicular hump. The flap was now passed into the neck through subcutaneous tunnel created superficial to the clavicle. The tunnel was made wide enough to permit easy delivery of the flap into the neck without compression. Suturing of the flap was done with 3-0 vicryl interrupted sutures, suction drains were placed. The donor site was always closed primarily which may require extensive mobilization of fasciocutaneous flaps.

Results :

Retrospectively, 100 patients were reviewed for study. These patients were classified as per primary site of tumor, TNM stage of the disease. Most tumors were advanced (T3 or T4a) lesion. Figure 1 shows that out of 100 patients 67 patients were classified in stage IV, 18 patients were in stage III, and 15 patients were in stage

I or II. Need for PMMC reconstruction is mostly needed for advanced cases.

Figure 2 shows distribution of primary site. Out of 100 cases 2 patients had parotid tumors, 2 patients had tonsil mass, 2 patients had advanced tongue carcinoma and near total glossectomy was done. Floor of mouth was primary site in 2 cases. Buccal mucosa and gingivo-buccal sulcus (GBS) involvement is commonly seen in Indian subcontinent; in our study 35 patients had such lesions. Most common site was buccal mucosa GBS. Lower alveolus was primary site in 30 patients that have undergone hemimandibulectomy. Out of these patients, 5 patients had undergone marginal mandibulectomy as bone erosion was not evident clinically or radiologically. Retro molar trigone (RMT) was 3rd common site in 25 patients that have undergone distal mandibulectomy. Due to proximity of bone in RMT area scarification of mandible segment was needed. Figure 3 shows that in majority of patients, (98) same side of muscle was harvested;

Figure 1: Distribution of cases as per disease stage

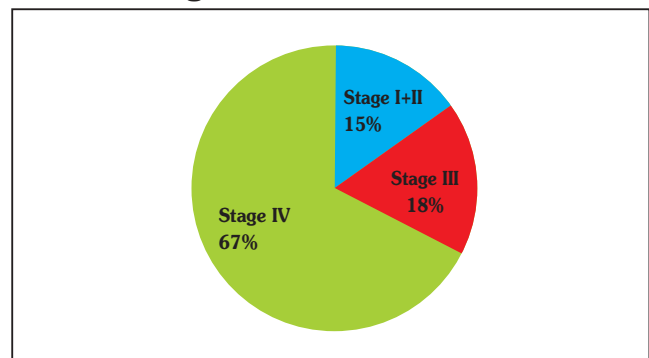


Figure 2 : Distribution of primary site of tumor

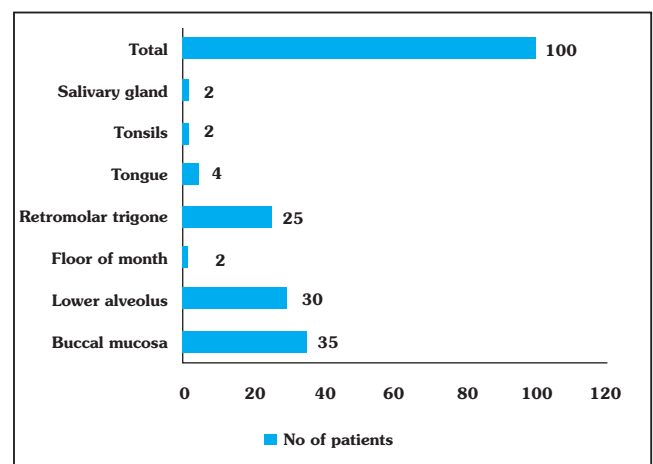


Figure 3: Laterality of donor site

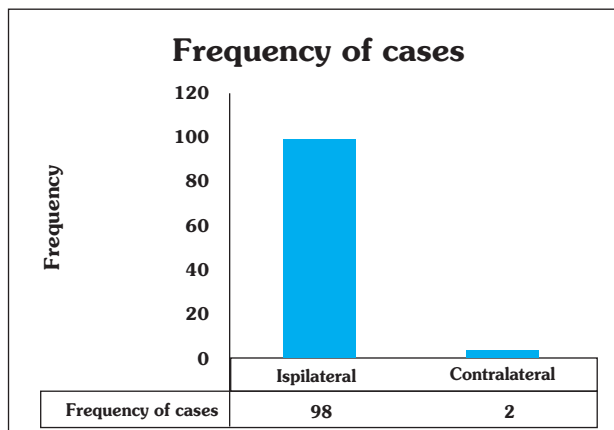


Table 1: Flap related complications

Complications	No. of Cases	Stage I, II	Stage III,	Stage IV
Total flap necrosis	Nil	-	-	-
Major flap necrosis	1			1
Minor flap necrosis	12		2	10
Fistula	12	1	2	9
Wound dehiscence	8			8
Hematoma	3		1	2
Infection (superficial and deep)	28	2	6	20

2 patients needed contra-lateral flap due to unavailability of same side muscle or previous history of surgery. 98 reconstructions were done as a primary procedure, and 2 were salvage procedure. Table 2 shows type of reconstruction and its relation with stages. PMMC flap was used to cover only mucosal defect in 84 patients, skin and mucosal in 16 patients.

Table 1 classifies flap related complications. None of the patients had total flap necrosis. 28 patients had superficial and deep infections which resolved by conservative management. Minor complications and donor site complications included fistulas that were managed conservatively; wound dehiscence not requiring additional surgery, local infections, seromas, and hematomas. Only 1 patient had major flap loss (more than 3 cm). No cases of total flap loss were reported.

On finding the correlation between effect of stage of the disease on occurrence of complications after

surgery, it was revealed that, correlation coefficient between Stage IV of the disease and Wound Dehiscence was 0.207 while the 'p' value was 0.039. It implies that the chances of occurrence of wound dehiscence as a complication is more common when surgery was done at 4th stage of the disease. Other complications, though found, were not statistically correlated with various stages of the disease. (Spearman's rank correlation coefficient was calculated)

Discussion :

In spite of more popularity of free flaps, PMMC flap continues to be the important tool in armamentarium of head neck surgeon due to high load and limited resources. ⁽¹¹⁾ The flap is easy to learn and learning curve is shorter. The reliability of the pedicled flaps is better than free flaps. Single team can work so logistic issues are also solved. ⁽¹²⁾ Pedicled flaps are best for salvage procedures following free flap failure. In patients with history of radiation therapy or chemotherapy due to unreliable recipient vessels pedicled flaps is most reliable option. Patients that are not fit for long surgery also makes them suitable candidate for PMMC. In patients with inadequate recipient vessels and less feasibility of microvascular surgery pedicled flaps are the first choice. In some situations pedicled flaps are used in combination with free flaps to reconstruct complex defects. ^(11, 13)

The available literature on PMMC flap showed varying range and rate of complications. That varies from 17 to 63%. ^(6-8, 10) In our series, we observed complication rate of 36% with 12% occurrence with minor flap necrosis. We did not observe total flap necrosis or major flap loss; which may be contributed to good soft tissue handling. Our results are comparable to those in the literature. ^(5, 7, 11, 14) The major advantage of PMMC flap is survival. Even in hands of experienced microvascular surgeon, flap success is never 100%. Free flaps follow all or none law most of the times. Failure shall necessitate further surgical intervention, psychological and economical trauma to the patient.

The factors that may contribute to major or total flap loss may be: Use of electrocautery versus knife, preservation versus removal of clavicular attachment of pectoralis major, planning of random portion of skin paddle out of the muscle, inclusion of rectus sheath. ^{(5, 7,}

Table 2: Type of Reconstruction technique as per stages of the disease

Type of reconstruction	Stage I, II	Stage III,	Stage IV	Total
Single paddle mucosal or skin	15	18	51	84
Bipaddle mucosa +skin	-	-	16	16

Table 3 : Correlation between effect of stage of the disease on occurrence of complications after surgery

Complications after surgery	Stages of disease					
	I, II		III		IV	
	Correlation Coefficient	Significance (2tailed)	Correlation Coefficient	Significance (2tailed)	Correlation Coefficient	Significance (2tailed)
Infection	-0.137	0.173	-0.002	0.982	0.106	0.293
Wound dehiscence	-0.124	0.219	-0.138	0.17	0.207	0.039
Fistula	-0.069	0.495	0.067	0.506	-0.003	0.979
Hematoma	-0.074	0.465	-0.082	0.415	0.123	0.221

¹¹⁾ Each one of them has advantages and disadvantages. Good electrocautery and lesser time contact with the tissues will decrease heat production and may give similar results. Preservation of clavicular head will give hump over the clavicle but will have less chances of pedicle torsion. Random portion of flap if designed; should be raised with ractus sheath. Rikimaru et al.,⁽¹⁵⁾ pointed out that positioning the skin paddle just medial to the nipple along 4th 5th and 6th intercostals spaces will encompass perforators arising from intercostal branches of internal thoracic artery. As main flow through internal thoracic artery is interrupted after elevating flap thus totally axial pattern flap may be raised by following this anatomic direction. Below the 7th rib blood supply comes from cataneous branches of superior epigastric artery. So, when portion of this skin is included that becomes axial pattern flap with random distal paddle.

Another pitfall was described by Cunha Gomes et al.,⁽¹⁶⁾ relates to the lateral pectoral nerve. Sometimes it runs above or in close relation with the pectoral pedicle. After raising the flap it may become taut and may strangulate the pedicle if not sacrificed. We divide this nerve in most of the cases so this phenomenon is not observed in our cases. Hematoma developed in 3 patients. On exploration major bleeders could not be identified. These patients were on antiplatelet drugs before surgery and it was stopped 72 hours prior surgery. Fistula was seen in 12 patients. 2 of them

needed resuturing and rests were managed by conservative method. The most difficult area to clean is anterior tripointer; that area is difficult to access and leads to salivary stagnation. Patients with poor oral hygiene during radiotherapy are potential candidates but we have not observed that in our study as once flap is stabilized then only radiation was started. In patients that have undergone marginal mandibulectomy and PMMC; extra care was taken so that vascular compromise does not occur.

Conclusion :

Comparing the versatility, easy learning curve and consistent design of pedicle, PMMC flap is more favored flap with acceptable cosmetic and functional outcomes. Our experience has shown low flap related complications with zero total flap necrosis. We recommend free flap as a first choice when feasible and practical. But with limited resources and heavy patient load PMMC flap is still a workhorse flap for head and neck reconstruction.

References:

1. Blakwell KE, Buchbinder D, Biller HF, Urken ML. Reconstruction of massive defects in head and neck: The role of simultaneous distant and regional flaps. *Head Neck* 1997;19:620-8.
2. Vijay R. Ramakrishnan, MD; William Yao, BS; John P. Campana, MD Improved Skin Paddle Survival in Pectoralis Major Myocutaneous Flap Reconstruction of Head and Neck Defects. *Arch Facial Plast Surg.* 2009;11(5):306-310. doi:10.1001/archfacial.2009.67.

3. McCrory al, Magnuson JS. Free tissue transfer versus pedicled flap in head and neck reconstruction. *Laryngoscope* 2002;112:2161-5.
4. Ariyan S. The pectoralis major myocutaneous flap: A versatile flap for reconstruction in the head and neck. *Plast Reconstr Surg* 1979;63:73-81.
5. Milenovic A, Virag M, Uglesic V, Aljinovic-Ratkovic N. The pectoralis major flap in head and neck reconstruction: First 500 patients. *J Craniomaxillofac Surg* 2006;34:340-3
6. Croce A, Moretti A, D'Agostino L, Neri G. Continuing validity of pectoralis major flap 25 years after its first application. *Acta Otorhinolaryngol Ital* 2003;23:297-304.
7. Liu R, Gullane P, Brown D, Irish J. Pectoralis major myocutaneous pedicled flap in head and neck reconstruction: Retrospective review of indications and results in 244 consecutive cases at the Toronto General Hospital. *J Otolaryngol* 2001;30:34-40.
8. Shah JP, Haribhakti V, Lorre TR, Sutaria P. Complications of pectoralis major myocutaneous flap in head and neck reconstruction. *Am J Surg* 1990;160:352-5.
9. Mayank Tripathi, Snjeev Parshad, Rajender Kumar Karwasra, Virender Singh. Pectoralis major myocutaneous flap in head and neck reconstruction: an experience in 100 consecutive cases. *National journal of Maxillofacial Surgery* 2015; 6:37-41.
10. Freeman JL, Walker EP, Wilson JS, Shaw HJ, The vascular anatomy of pectoralis major myocutaneous flap. *Br J Plast Surg* 1981;34:3-10.
11. Varnian JG, Carvalho AL, Carvalho SM, Mizobe L, Magrin J, Kowalski LP. Pectoralis major and other myofascial/ myocutaneous flaps in head and neck cancer reconstruction: Experience with 437 cases at a single institute. *Head Neck* 2004;26:1018-23.
12. Talesnick A, Markowitz B, Calcaterra T, Ahn C, Shaw W. Cost and outcome of osteocutaneous free tissue transfer versus pedicled soft tissue reconstruction for composite mandibular defects. *Plast Surg* 1996;97:1167-78.
13. Mclean JN, Carlson GW, Losken A. The pectoralis major myocutaneous flap revisited: A reliable technique for head and neck reconstruction. *Ann Plast Surg* 2010; 64:570-3.
14. El-Marakby HH. The reliability of pectoralis major myocutaneous flap in head and neck reconstruction. *J Egypt Natl Canc Inst* 2006;18:41-50.
15. Rikimaroo H, Kiyokawa K, Inoue Y, Tai Y. Three dimensional anatomical vascular distribution in the pectoralis major myocutaneous flap. *Plat Surg* 2005; 115:1342-52.
16. Cunha-Gomes D, Chaudhary C, Kavarana NM. Vascular compromise of the pectoralis major myocutaneous flap in head and neck reconstruction. *Ann Plast Surg* 2003; 51:450-4.