

Synchronous Double Malignancy in Previously Kidney Transplant Patient: A Rare Case Report

Goutam Koushal*, Tankshali Rajen**, Tripathi Umank***

Abstract:

In the past few decades, great advances have been made in the field of solid-organ transplantation that leads to improved survival. However, improved survival rates have also led to prolonged exposure to chronic immunosuppression, which increases the risk for the development of post transplant malignancies.

Keywords: Immunosuppression, Malignancy, Post transplant, Synchronous.

Introduction:

With early diagnosis and improved management of post-transplant infections and cardiovascular complications, post-transplant malignancy has become an important cause of mortality among organ transplant recipients. The overall incidence of malignancy after renal transplantation has been reported as being 3–5 times higher compared with the general population. ^(1,2)

The most common cancers among organ transplant recipients are skin cancer and post-transplant lymphoproliferative disorder. ^(3,4) The major reasons for this increased risk are thought to be perturbation in immune surveillance mechanisms secondary to the chronic use of immunosuppressive agents as well as infection with oncogenic viruses. ⁽⁵⁾ Here we report a case of synchronous double primary carcinoma (carcinoma right cheek skin and gastric carcinoma) in a renal allograft recipient.

Case Report :

A 42 years old male presented in Surgical Oncology Department at Gujarat Cancer and Research Institute, Ahmedabad, with an ulcerative lesion over right cheek and adjacent parotid region since last three months. Patient was hepatitis B positive from last 5 years and has history of renal transplantation 19 years back for focal segmental glomerulonephritis, His elder brother came forward as a voluntary kidney donor and was found fit to donate a kidney. He was on azathioprine and steroids and lamivudine therapy. On routine

laboratory examination his serum creatinine was 0.79 mg/dl, rest of the parameters were in normal range, Biopsy of cheek lesion showed squamous cell carcinoma. During work up of patient another lesion was found on the lesser curvature of stomach on upper GI endoscopy, biopsy of that lesion showed adenocarcinoma. CT neck and CT abdomen showed primary parotid lesion with nodal metastasis and another primary malignant lesion in stomach with liver metastasis. As the disease was already advanced, patient was managed with palliative chemotherapy resulted in some symptomatic improvement, then patient was on regular follow up.

Figure 1: Light microscopy image showing features suggestive of squamous cell carcinoma

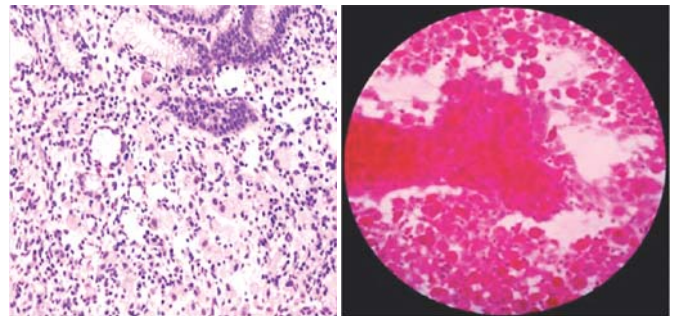
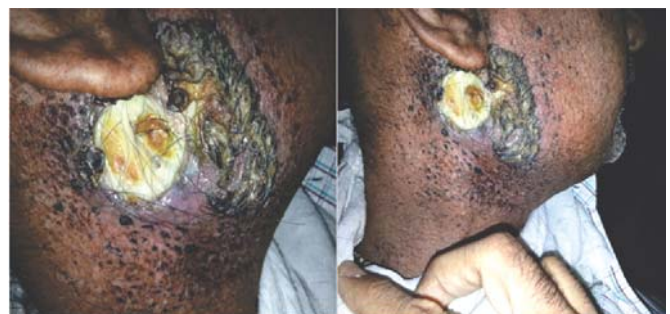

Figure 2, 3: Skin lesion over right cheek



* Registrar Mch oncosurgery,
 ** Professor & Head of Unit,
 *** Assistant Professor Gujarat Cancer Research Institute (GCRI), New Civil Hospital campus, Asarwa, Ahmedabad, Gujarat, India.
 Correspondence: drkg81@gmail.com

Figure 4: CT image showing lesions over right cheek

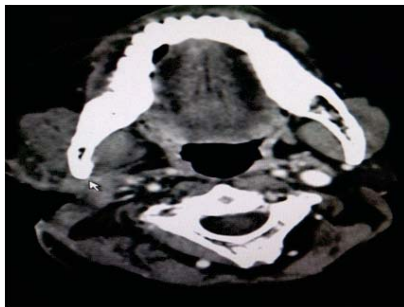

Figure 6: Liver metastasis

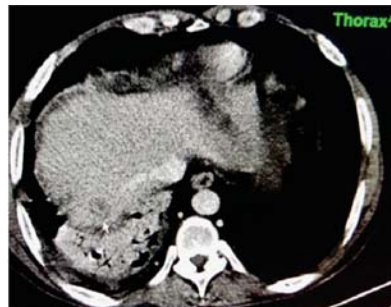

Figure 5: Lesion over lesser curve of stomach

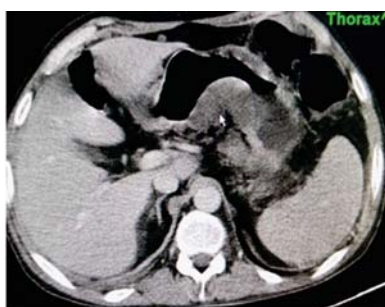
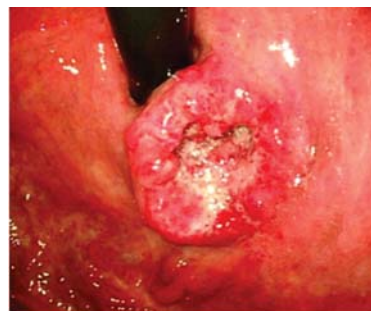
Figure 7: Endoscopy view of lesser curvature ulcer



Discussion :

Single primary neoplasms are frequently reported in renal allograft recipients. However, synchronous double primary carcinomas in a single patient are rare. We report synchronous double primary carcinomas occurring in a single patient.

Very few cases of double primary carcinomas have been reported in the literature in renal allograft recipients. In one case report,⁽⁶⁾ two different primary lung malignancies occurring simultaneously were reported in the same patient.

There is no report on simultaneous skin and gastric carcinoma to our knowledge. The increased risk of cancer in allograft recipients has been related to loss of immuno- surveillance, activation of oncogenic viruses, chronic immunostimulants or to treatment with immunosuppressive drugs.^(1,7) The literature search revealed that the most important factors that can influence the chance of developing post transplant malignancy is immunosuppression. Our patient was on prolonged posttransplant immunosuppression, which could have predisposed him for developing carcinoma.

Conclusion :

Malignancy has become one of the major causes of death after transplantation. In this case report. It shows synchronous double primary lesion in a posttransplant patient indicating the need of proper surveillance and routine cancer screening in these cases to rule out multiple primary malignancy.

References:

1. Birckland SA, Lokkegaard H, Storm HH. Cancer risks in patients on dialysis and after renal transplant. *Lancet* 2000; 355: 1886-7.
2. Peto J. Cancer epidemiology in the last century and the next decade. *Nature* 2001; 411:390-5.
3. Penn I. Cancers in renal transplant recipients. *Adv Ren Replace Ther* 2000; 7:147-56.
4. Zeir M, Hartschuh W, Wiesu M, Lehnert T, Ritz E. Malignancy after renal transplantation. *Am J Kidney Dis* 2002;39:ES.
5. Joshi K, Jha V. Malignancies following kidney transplantation. *J Nephrol Ren Transplant* 2009; 2:94-103.
6. Forslund T, Hortling T, Timonen T, Laasonen L. Two different primary lung malignancies after successful kidney transplantation. *Acta Radiol Oncol* 1984; 23:6.
7. Bunet PM. The concept of immunological Surveillance. *Progr Exp Tumour Res* 1970; 13:1.