

Clinical Evaluation of an Outbreak of Epidemic Keratoconjunctivitis

Hemaxi Desai*, Surohi Shah**, Aparna Singhal***, Sanjeev Prasad****

Abstract :

Introduction: Epidemic keratoconjunctivitis is the only adenoviral syndrome with follicular conjunctivitis associated with significant corneal involvement. The infection is bilateral in a majority of patients. Very few studies are done because of its self limiting nature and because complications if occur, are rarely sight threatening. **Material and Methods:** Clinical characteristics in the patients presenting with viral conjunctivitis in Ophthalmology department of our hospital starting from September 2012 to January 2013 were studied. All the patients were treated with lubricating agents and topical steroids when indicated. Patients were followed till the complete resolution of symptoms. **Results:** A total of 54 patients (84 eyes) with the diagnosis of epidemic keratoconjunctivitis were identified. All the patients were given lubricants to start with. 52% patients required topical steroids, of which 2% patients required high strength steroid. **Conclusion:** Adenoviral conjunctivitis is a self-limiting disease that tends to resolve spontaneously within 1 to 3 weeks in most cases. Because there is no known efficient antiviral treatment against human adenoviruses, management is focused on symptomatic relief. Careful patient education regarding hygiene measures and strict implementation of hospital infection protocol can curtail the epidemic.

Keywords: Epidemic keratoconjunctivitis(EKC), Superficial punctuate keratopathy(SPK)

Introduction:

Originally isolated in 1953 from surgically removed human adenoids, adenoviruses cause a broad spectrum of diseases, including infections of the upper respiratory tract and ocular surface, meningoencephalitis, acute hemorrhagic cystitis of young boys, diarrhoea of children and respiratory and hepatic failure in the immunocompromised host.

Adenoviruses are nonenveloped, double-stranded DNA viruses with an icosahedral capsid. Human adenoviruses are classified into 6 subgroups (A to F) that consist of 57 serotypes.⁽¹⁾ Transmission of the viruses occurs by close contact with respiratory or ocular secretions, fomites, contaminated swimming pools, or through contaminated instruments or eyedrops in physicians' offices. Each subgroup (A to F) of adenoviruses, and to a lesser degree, each serotype possesses unique tissue tropisms that reveal the association of specific adenoviruses with distinct clinical syndromes, which are as follows⁽²⁾:

Simple follicular conjunctivitis (multiple serotypes)

Pharyngoconjunctival fever (most commonly serotype 3 or 7)

Epidemic keratoconjunctivitis (EKC; usually serotype 8, 19 or 37, subgroup D)

Simple follicular conjunctivitis is self limited, not associated with systemic disease and often so transient that patients do not seek care. Epithelial keratitis, if present, is mild. Pharyngoconjunctival fever is characterized by fever, headache, pharyngitis, follicular conjunctivitis and preauricular lymphadenopathy. The systemic signs and symptoms may often mimic influenza. Any associated epithelial keratitis is mild. Epidemic keratoconjunctivitis is the only adenoviral syndrome with follicular conjunctivitis associated with significant corneal involvement. The infection is bilateral in a majority of patients and may be preceded by an upper respiratory infection.

Diagnosis is mostly based on clinical findings; laboratory diagnosis is rarely indicated. Diagnosis is suggested in the setting of bilateral follicular conjunctivitis associated with petechial conjunctival hemorrhages, conjunctival pseudo membrane or frank membrane formation, or later in the clinical course, the presence of bilateral subepithelial infiltrates.

* Associate Professor, ** Assistant Professor, **** Senior Resident, Department of Ophthalmology, GCS Medical College Hospital & Research Centre, Ahmedabad

*** Senior Resident, Department of Ophthalmology, Maharaja Agrasen Medical College, Haryana

Correspondence : surohishah@yahoo.com

Since adenovirus can be excreted for prolonged periods, the presence of virus does not necessarily mean it is associated with disease. As epidemic keratoconjunctivitis is a self limiting condition, therapy is primarily supportive, except in few cases where use of topical steroids is indicated.^(1,2,3) We have studied the clinical characteristics of an outbreak of EKC during the period of September 2012 to January 2013; wherein 54 patients (84 eyes) were evaluated based on clinical diagnosis, clinical course and the required treatment modalities.

Aims and Objectives:

- To study clinical pattern of the outbreak of viral keratoconjunctivitis.
- To assess visual and clinical prognosis of the disease.
- To derive the best possible treatment modality giving symptomatic relief and early recovery.
- To prevent complications of viral keratoconjunctivitis.
- To prevent spread of the outbreak in community by patient education.

Material and Methods:

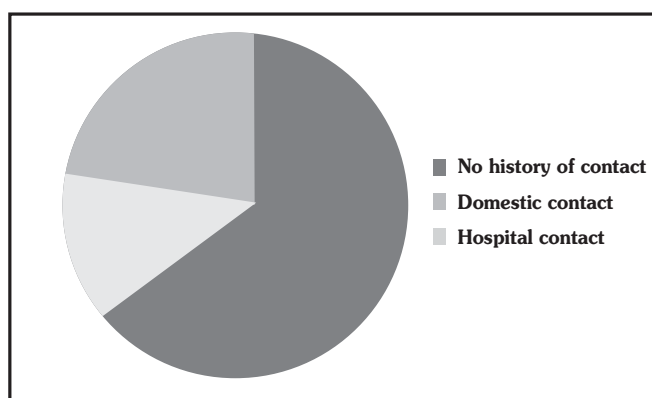
We studied clinical characteristics in the patients presenting with viral conjunctivitis in Ophthalmology department of our hospital starting from September 2012 to January 2013. Thorough history, including mode of acquisition of infection was noted, visual acuity assessment and anterior segment evaluation with slit lamp biomicroscopy were done. The diagnosis was based on the clinical findings. All the patients were treated with 1% carboxymethylcellulose eye drops. Patients having conjunctival pseudomembranes and visually significant keratitis were started with low strength steroids like 0.1% fluorometholone or 0.5% loteprednol eye drops under close observation and were followed up till complete resolution of signs and symptoms. Interval history, visual acuity assessment and anterior segment evaluation were done at each visit. Complications, if any were also noted and managed accordingly.

Results :

A total of 54 patients (84 eyes) with the diagnosis of

epidemic keratoconjunctivitis were identified. The mean age of presentation was 31.25 +/- 17.3 years. Thirty eight patients were less than 40 years of age. (P< 0.001) Out of them, 26 patients were males and 28 were females. Twenty four patients had unilateral and 30 patients had bilateral ocular involvement on presentation. The mean day of presentation after onset was 4th. Twenty one patients had history of previous contact from an infected person.(Fig. 1)

Figure 1: Diagram showing history of contact



Two patients had associated upper respiratory tract infection. Eight patients had preauricular lymphadenopathy. Redness was the commonest presenting symptom. Petechial hemorrhages and conjunctival follicles were the commonest presenting signs. Figure 2 indicates presenting signs of the epidemic.(Fig. 2)

Figure 2: Presenting signs of epidemic keratoconjunctivitis outbreak

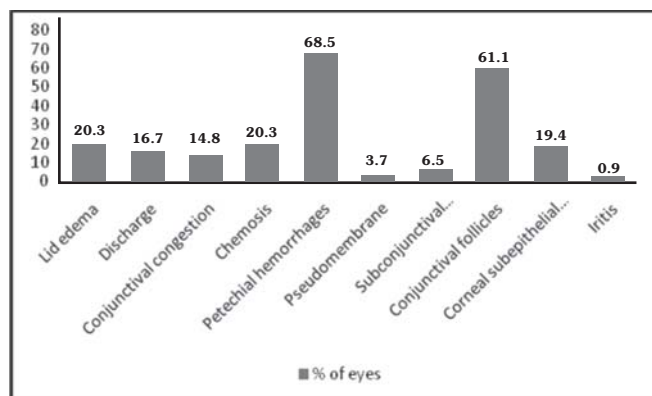
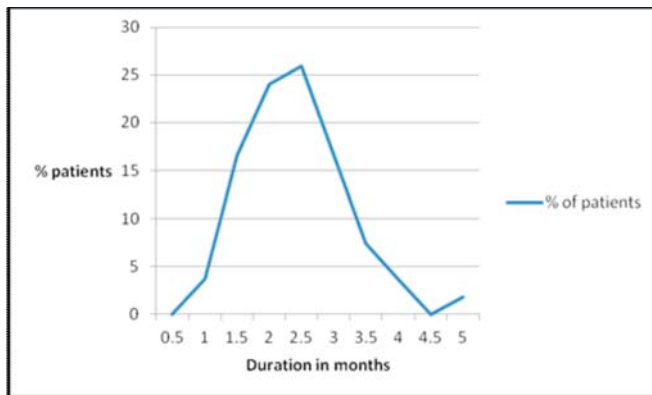
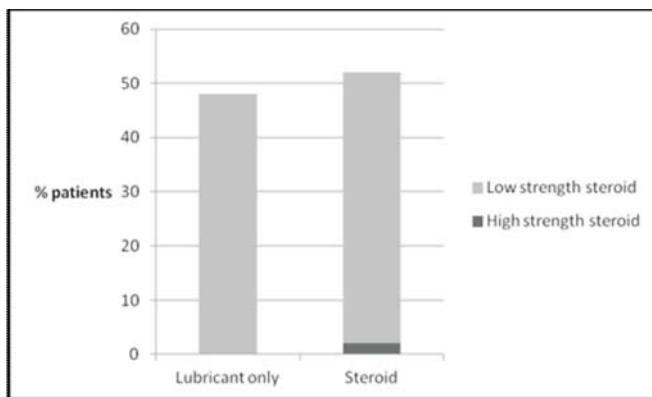


Figure 3: The course of the epidemic

The epidemic of EKC was of 5 months duration starting from September 2012 to January 2013. Peak of the epidemic was observed after one month of the start, with 14 patients. The number of cases came down to zero gradually after next four months.(Fig. 3)

Figure 4 indicates the number of patients requiring lubricants only, versus those requiring topical steroids as well.

Figure 4: Patients requiring lubricants only vs. those requiring steroids in addition

All the patients were given lubricants to start with. 52% patients required topical steroids of which 2% patients required high strength steroid.

During the study of the epidemic, 21 eyes developed superficial punctate keratopathy (SPK), 6 had iritis, 6 had pseudomembrane and 1 eye had corneal epithelial defect with filaments within the first week of follow up, while 5 eyes developed SPKs within the second week.

In 10 patients of those unilateral to start with, other eye involvement occurred during first week of follow up.

Mean time required for complete resolution of symptoms was 17 days.

Discussion :

Adenoviruses are the most common cause of acute viral infection of the conjunctiva, accounting for up to 75% of cases of conjunctivitis.⁽⁴⁾ It is a highly contagious disease occurring in epidemics, but very few studies are done because of its self limiting nature and because complications if occur, are rarely sight threatening.

In our study, the mean age of presentation was 31 years with involvement of all age groups with no sex predilection which is similar to data from Germany.⁽⁵⁾

EKC typically occurs in 20-30 years age group.^(1,2) In our study, the patients having less than 40 years of age were 72%($P < 0.001$).

EKC tends to occur in closed institutions. The risk of infection from domestic contact is approximately 10%, increasing in cases with prolonged infection.⁽⁶⁾ In our study, 24% patients gave history of domestic contact while 14% patients had a history of recent visit at Ophthalmology unit. Nosocomial EKC infections are common, and outbreaks in ophthalmology units may impose restrictions on clinical practices, including delay of eye surgery, early release of inpatients from hospital, and closure of Ophthalmology wards. The incubation period varies between 4 to 24 days, and the symptoms tend to last for 7 to 21 days. The patient may remain infectious for 10 to 14 days after symptoms start. They are considered infectious till redness and tears persist. EKC is predominantly a unilateral condition in its initial phase, but can become bilateral in up to 70% of cases. In our study, 44% patients had unilateral eye involvement at presentation which progressed to 74% bilateral involvement. The symptoms last for average 17 days.

A common complication from EKC is multifocal subepithelial infiltrates which is considered pathognomonic of adenoviral infection. They are observed in up to 50% of cases.^(2,7) 19% of eyes had SPKs in our study group. These focal lesions may

represent a cellular immune reaction against viral antigens deposited in the corneal stroma under the Bowman membrane.⁽⁸⁾ Subepithelial infiltrates can persist for weeks to years. They may cause visual impairment if the infiltrates involve the visual axis. Most of these infiltrates tend to resolve spontaneously without scarring. The use of topical corticosteroids may hasten recovery, but does not affect the long-term outcome.⁽⁹⁾

The formation of pseudomembranes is another frequent complication in EKC which was present in 4% of eyes. Six patients developed mild iritis during the course of the disease which is indicative of iris irritation, which may occur in connection with any keratitis. One patient developed corneal filaments with epithelial defect resistant to lubricants and had to be given a bandage contact lens for the same.

The diagnosis of adenoviral conjunctivitis is usually made on the basis of symptoms and clinical findings. Laboratory testing is typically not necessary, but can be helpful in confirming the diagnosis.⁽¹⁰⁾ Testing includes cell culture, PCR, direct immunofluorescence, and rapid antigen detection immunoassays. The tests are less commonly performed because of the necessity for elaborate equipment, trained laboratory personnel, and the significant delay in obtaining results.⁽¹¹⁻¹⁵⁾

Because there is no effective treatment for adenoviral conjunctivitis and its complications, good hygiene practices, such as rigorous disinfection of hands and instruments, are essential for prevention of spread of the infection.^(1,2,3) Steroid treatment should be restricted to complicated cases with pseudomembranes or subepithelial infiltrates where visual acuity is significantly impaired.^(15,16) Virustatic agents such as trifluridine, vidarabine, and ganciclovir are only mildly effective against adenovirus, and current data with regard to their efficacy in treatment adenoviral conjunctivitis are still controversial.^(17,18,19) The use of gloves, disposable tonometer heads, and single-patient eye drop dispensers may reduce transmission.⁽²⁰⁾

Conclusion :

Adenoviral conjunctivitis is a self-limiting disease that tends to resolve spontaneously within 1 to 3 weeks in most cases. Because there is no known efficient antiviral treatment against human adenoviruses, management is focused on symptomatic relief with cold compresses and lubrication. Topical corticosteroids may be indicated only if vision-threatening complications arise.⁽⁵⁾ Late scarring may be treated by phototherapeutic keratectomy.⁽²¹⁾ Prevention is important to control the propagation of the infection. Implementation of systematic hospital infection control protocol against adenoviral infection is required in addition to general measures like hand washing and disinfection of instruments.⁽²²⁾ Strict adherence to hygienic measures and establishment of an adenoviral infection control program can greatly reduce the incidence of community outbreaks.

References :

1. Ghebremedhin B. Human adenovirus: viral pathogen with increasing importance. *Eur J Microbiol Immunol (Bp)*. 2014;4:26-33
2. Gonzalez-Lopez JJ, Morcillo-Laiz R, Munoz-Negrete FJ. Adenoviral keratoconjunctivitis: an update. *Arch Soc Esp Ophthalmol*. 2013;88:108-15
3. Meyer-Rusenberg B, Loderstadt U, Richard G, et al. Epidemic keratoconjunctivitis: the current situation and recommendations for prevention and treatment. *Dtsch Arztebl Int*. 2011;108:475-80
4. Woodland RM, Darougar S, Thaker U, et al. Causes of conjunctivitis and keratoconjunctivitis in Karachi, Pakistan. *Trans R Soc Trop Med Hyg*. 1992;86:317-20
5. Adlhoeh C, Schoneberg I, Fell G, et al. Increasing case numbers of adenovirus conjunctivitis in Germany, 2010. *Euro Surveill*. 2010;15(45). pii: 19707.
6. Guyer B, O'Day DM, Hierholzer JC, et al. Epidemic keratoconjunctivitis: a community outbreak of mixed adenovirus type 8 and type 19 infection. *J Infect Dis*. 1975;132:142-50
7. Tabbara KF, Omar N, Hammouda E, et al. Molecular epidemiology of adenoviral Keratoconjunctivitis in Saudi Arabia. *Mol Vis*. 2010;16:2132-6
8. Jones BR. The clinical features of viral keratitis and a concept of their pathogenesis. *Proc R Soc Med*. 1958;51:917-24
9. Laibson PR, Dhiri S, Oconer J, et al. Corneal infiltrates in epidemic keratoconjunctivitis. Response to double-blind corticosteroid therapy. *Arch Ophthalmol*. 1970;84:36-40

10. Udeh BL, Schneider JE, Ohsfeldt RL. Cost effectiveness of a point-of-care test for adenoviral conjunctivitis. *Am J Med Sci.* 2008;336:254-64
11. Darougar S, Walpita P, Thaker U, et al. Rapid culture test for adenovirus isolation. *Br J Ophthalmol.* 1984;68:405-8
12. Elnifro EM, Cooper RJ, Klapper PE, et al. Diagnosis of viral and chlamydial keratoconjunctivitis: which laboratory test? *Br J Ophthalmol.* 1999;83:622-7
13. Kowalski RP, Karenchak LM, Romanowski EG, et al. Evaluation of the shell vial technique for detection of ocular adenovirus. *Community Ophthalmologists of Pittsburgh, Pennsylvania. Ophthalmology.* 1999;106:1324-7
14. Liu C, Llanes-Rodas R. Application of the immunofluorescent technic to the study of pathogenesis and rapid diagnosis of viral infections. *Am J Clin Pathol.* 1972;57:829-34
15. Laibson PR, Green WR. Conjunctival membranes in epidemic keratoconjunctivitis. *Arch Ophthalmol.* 1970;83:100-2
16. Romanowski EG, Roba LA, Wiley L, et al. The effects of corticosteroids of adenoviral replication. *Arch Ophthalmol.* 1996;114:581-5
17. Trousdale MD, Goldschmidt PL, Nobrega R. Activity of ganciclovir against human adenovirus type-5 infection in cell culture and cotton rat eyes. *Cornea.* 1994;13:435-9
18. Ward JB, Siojo LG, Waller SG. A prospective, masked clinical trial of trifluridine, dexamethasone, and artificial tears in the treatment of epidemic keratoconjunctivitis. *Cornea.* 1993;12:216-21
19. Waring GOE, Laibson PR, Satz JE, Joseph NH. Use of vidarabine in epidemic keratoconjunctivitis due to adenovirus types 3, 7, 8, and 19. *Am J Ophthalmol.* 1976;82:781-5
20. Azar MJ, Dhaliwal DK, Bower KS, et al. Possible consequences of shaking hands with your patients with epidemic keratoconjunctivitis. *Am J Ophthalmol.* 1996;121:711-2
21. Yamazaki ES, Ferraz CA, Hazarbassanov RM, et al. Phototherapeutic keratectomy for the treatment of corneal