

## Thoracic Actinomycosis in a Paediatric Patient: A Case Report

Jitesh Raval\*, Mansi U. Shah\*\*, Afroz Bloch\*\*\*

### Abstract :

Actinomycosis is usually a multi bacterial infection, wherein the major pathogen belongs to the Genus *Actinomyces*. The prevalence of this infection has decreased worldwide, but a noticeable proportion of the infection is seen in the developing world. Cervico facial type is the commonest with thoracic variety responsible for 15 % of cases.<sup>(1, 2)</sup> The clinical picture in thoracic type is more often than not misleading & confused with pulmonary neoplasm, abscess & other pulmonary pathologies.<sup>(1)</sup> Here, we are presenting a case of actinomycotic pyopneumothorax complicated by empyema & pyopericardium in a paediatric patient .

**Key words:** Actinomycosis, Pericardial, Thoracic.

### Introduction :

Actinomycosis is a chronic, suppurative, granulomatous infection caused by gram positive, non acid fast, anaerobic bacteria of the genus *Actinomyces*. Other bacteria may cause synergistic infections with the *Actinomyces spp.*, like *Rothia*, *Arachnia*, *Bifidobacterium*.<sup>(2)</sup> Actinomycosis mainly affects cervico facial, thoracic & abdomino pelvic areas; cervicofacial being the commonest, followed by thoracic & then, abdominopelvic type.<sup>(2)</sup> Clinically, it is characterized by indurated subcutaneous nodules in the affected region, draining sinuses, purulent sputum production, hemoptysis, pleuritic pain & fever. *Actinomyces spp.* is a normal inhabitant of the oropharyngeal & gastrointestinal tract. The pulmonary type of actinomycosis occurs most commonly by aspiration of oropharyngeal or gastropharyngeal secretions.<sup>(3, 4)</sup> Dental caries & improper dental hygiene, both are also found to be responsible for the same.<sup>(2, 5)</sup> Immunocompromised status of the host is again an added favourable factor. The infection generally shows a male preponderance & commonly affects adults.<sup>(2, 6)</sup> Cardiac tamponade secondary to thoracic actinomycosis, as in this case is a rare clinical entity.<sup>(7)</sup>

### Case report :

A 5 year old male patient was admitted to a private hospital at Nadiad with complaints of fever & cough since 15 days. He was treated with intravenous fluids & antibiotics of unknown regimen for a period of 10 days during which his condition deteriorated with increased expectoration, respiratory distress & without any amelioration of the presenting symptoms. The child was then referred to a private hospital at Ahmedabad having had the same complaints in an aggravated form since 25 days now. The child was a full term, home delivered baby with uneventful birth & neonatal period. There was no past history of any major illnesses. The developmental history of the child was normal with complete vaccination for his age. No family history of tuberculosis, asthma or other major illness was noted. On admission, the patient was drowsy, febrile at 100° F, having tachycardia at 150/minute. The patient had cold peripheries & laboured breathing. The patient was intubated immediately on IPPV (Intermittent Positive Pressure Ventilation). Intravenous antibiotics were started & CT chest was done which identified signs of right sided pyopneumothorax with necrotized right upper lobe & patchy consolidation in right middle zone accompanied by multiple broncho-pleural fistulae (Fig. 1). Poor perfusion due to cardiac tamponade & massive pericardial effusion was detected. The effusion was tapped & inter-costal drainage tube was

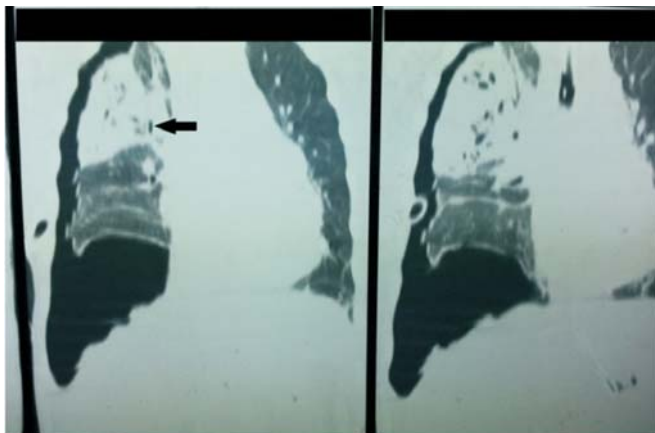
\* Paediatric Intensivist, Ahmedabad, Gujarat, India.

\*\* Consultant Microbiologist, Sarthak Microbiology Laboratory, Ahmedabad, Gujarat, India.

\*\*\* Tutor, Dept of Microbiology, GCS Medical College, Hospital & Research Center, Ahmedabad, Gujarat, India.

Correspondence : dr.roz.saiyed@gmail.com

**Figure 1 : CT Chest showing right sided necrotizing pneumonia with hydropneumothorax**



The drained pus showed 5.2 gm/dl protein, 7mg/dl sugar, 18,000/cmm total WBCs, of which 95 % were polymorphs & 5% lymphocytes. Culture of the pus was negative. A planned thoracotomy was performed with the necrotized posterolateral part of the right upper lobe removed & major bronchopulmonary fistulae repaired. The tissue removed from the right lung was sent for microbiological examination. On direct microscopy, *Actinomyces* was identified as gram positive, non-acid fast, filamentous structure. It was differentiated from fungi due to the presence of narrower filaments breaking up into coccoid forms. The sample was cultured aerobically & anaerobically. Growth of any bacteria was not noted aerobically. The growth observed anaerobically; microscopic examination revealed branching filamentous gram positive bacilli resembling *Actinomyces*. The patient was diagnosed with actinomycosis, as the clinical picture of the patient with a pyogenic pathology, extensive lesion involving the pleura & the pericardium and the microbiology report were synchronous. Patient was given amoxicillin & continued for 6 months post discharge. Patient improved hemodynamically & was extubated on 5<sup>th</sup> day of admission. Follow up echocardiography revealed an improved cardiac status. The patient was started with oral diet from 15<sup>th</sup> day onwards & on 31<sup>st</sup> day the ICD was removed. On discharge, the patient was afebrile, taking orally, gaining weight regularly.

**Discussion :**

*Actinomyces*, a heterogenous group of bacteria producing branching filaments, have a misnomer

name. It appears to signify a fungus; which it is not. Its nomenclature is very famously because of its ray-like morphology. Doing justice to its name is its clinical presentation; again a misleading bread crumb. Majority of the cases of thoracic actinomycosis are initially diagnosed as bronchogenic carcinoma, abscess or empyema; clinically as well as from X ray findings. This fact alarmingly increases the morbidity, as the disease remains hidden undiagnosed in the shadows of other clinical syndromes. So much so, that there are instances in the scientific literature where the disease was diagnosed post-mortem.<sup>(3)</sup> Also, these bacteria are commensals in the human digestive tract, produce no harm in a host with an adequate immune system and their infection doesn't lead to overtly indicative symptoms. So the clinical suspicion becomes all the more difficult. In our case also, initial reports for the drained pus were negative for culture, but post-thoracotomy the removed tissue showed presence of *Actinomyces*. Majority cases have so been diagnosed post-operatively.<sup>(8, 9)</sup> *A. israeli* is the main implicated species in humans.<sup>(2, 10)</sup> Pathogenicity of *Actinomyces* develops when the host immunity lowers or when they reach an unusual site in the host body. Multi organism affliction gets well explained by the declined host immunity. In the present case, the child did not seem to be immunocompromised but the predisposing factor appears to be improper dental hygiene; as is common in paediatric age group & is also cited in numerous such reports.<sup>(2, 5, 7, 10)</sup> Occurrence of the disease in paediatric age group and with the involvement of pericardium is a very rare clinical entity.<sup>(2, 7)</sup> The presenting symptoms are variable; again they don't help much in the diagnosis. Cough and purulent sputum are common presentations.<sup>(8)</sup> The symptoms of our patient were mainly pulmonary without any typical presentation of draining sinuses. This atypical presentation of the pathogen masks its presence. Pleural involvement in thoracic actinomycosis, as in present case is very rare, seen in only 20 % cases.<sup>(11)</sup> Pulmonary actinomycosis complicated by pleuro-pericardial involvement has been reported, with aspiration pneumonia & periodontal disease being major risk factors. *Actinomyces* are sensitive to almost all antibiotics; drug of choice being penicillin.<sup>(2, 6, 7, 8)</sup> Its treatment is thus easy, with surgical intervention needed in extensive tissue lesions.<sup>(9)</sup>

**Conclusion :**

Although actinomycosis is not a common infection, an iceberg phenomenon cannot be ruled out. The causes may be underdiagnosis or its untargeted treatment with the face of some other infection. Suspicion & diagnosis rest on a multidisciplinary approach in investigations. If the CT scan shows pericardial abnormality with associated pulmonary pathology, actinomycosis should never be left untouched. Considering the re-emergence of almost obsolete infections, actinomycosis is one to be checked out for.

**References :**

- Jensen BM, Kruse-Andersen S, Andersen K. Thoraco-pleural actinomycosis presenting like diffuse pulmonary embolism. Thorac Cardiovasc Surg 1988; 36(5):284-6.
- Mabeza GF, Macfarlane JM. Pulmonary actinomycosis. Eur Respir J 2003; 21:545-51.
- Cavin R, Besson A, Loosli H, Leuenberger P, Jost A. Pleuro-pulmonary actinomycosis. Report of 4 cases. Schweiz Med Wochenschr 1980; 110(37):1328-34.
- Yoshihiro K et al. Thoracic actinomycosis with mainly pleural involvement. J Infect Chemother 2004; 10:172-7.
- Garini G, Bordi C, Mazzi A, Savazzi G, Tosi C. Thoracic actinomycosis with lung, mediastinal & pericardial involvement. A case report. Recenti Prog Med 1995; 86(3):107-11.
- Patel KB, Gupta G, Shah M, Patel P. Pulmonary actinomycosis in fine needle aspiration cytology. J Cytol. 2009; 26(2): 94-96.
- Slutzker DA, Claypool WD. Pericardial actinomycosis with cardiac tamponade from a contiguous thoracic lesion. Thorax 1989; 44:442-3.
- Coodley EL, Yoshinaka R. Pleural effusion as the major manifestation of actinomycosis. Chest 1994; 106:1615-17.
- Jensen BM, Kruse-Andersen S, Andersen K. Thoracic actinomycosis. Scand J Thorac Cardiovasc Surg. 1989; 23(2):181-4.
- Kedmi M et al. Thoracic actinomycosis with extension of the infection to the pericardium and chest wall. IMAJ 2007; 9:490-1.
- Touboul JL, Chaussade F, Desvignes B, Mangeney T, Bidault C. Isolated pleural actinomycosis. Apropos of 2 cases. Rev Pneumol Clin 1990; 46(2):69-72.

Product Portfolio, for your Patients of

# Breast Cancer



**Daxotel™**  
Docetaxel  
*The Superior Choice*



**Gemita®**  
Gemcitabine  
*Maximize Benefits*



**Intaxel®**  
Paclitaxel  
*Trusted Brand of Paclitaxel*

**ZOCITAB** Capecitabine  
*Effective Therapy  
Extended Compliance*



**Nanoxel™**  
Paclitaxel Nanoparticle  
*Nano Edge Paclitaxel*



**VINELBINE**  
Vinorelbine



**ANTHRACIN®**  
Your EpiRUBicin



**FRESENIUS  
KABI**  
caring for life

For further detailed information please contact  
 Fresenius Kabi India Pvt. Ltd.  
 A-3, MIDC, Ranjangaon Ganpati, Taluka Shirur,  
 District Pune, PIN - 412220, Maharashtra, India  
 Telephone: +91 20 2663 4701 - 4707  
 Fax: +91 20 2663 4710  
 Website: www.fresenius-kabi.co.in

ONC001CE10010011001