

## Ovarian Fibroma Presented As Meigs Syndrome: A Case Report

Biren Parikh\*, Pragna Sharma\*\*, Swati Parikh\*\*\*, Hrushikesh Surti\*\*

### Abstract :

The triad of ascites, pleural effusion and benign ovarian fibroma & related tumours is defined as Meigs syndrome. It is a rare clinical entity. This syndrome may lead to a mistaken impression of ovarian malignancy & inoperable ovarian neoplasm due to associated clinical findings of ascites & pleural effusion. We report a case of 65 years old female patient presenting with pain & heaviness in abdomen and dyspnoea with non-productive cough. Clinical and radiological findings revealed a mass in pelvis with ascites & right sided pleural effusion which mimicked an ovarian malignancy. However, histopathological examination disclosed an ovarian fibroma which is a benign tumour. During postoperative follow up, the ascites & pleural effusion were found to be resolved.

**Key Words :** Ascites, Pleural effusion, Meigs syndrome, Ovarian fibroma.

### Introduction :

In the WHO histopathological classification of tumors of the ovary, fibroma is classified under the sex cord - stromal tumors.<sup>(1)</sup> Ovarian fibroma is almost always benign in nature. However, sometimes it is presented as a Meigs syndrome consisting of associated findings of ascites & pleural effusion which may masquerade as carcinoma with malignant effusions. We report a rare case of Meigs syndrome.

### Case Report :

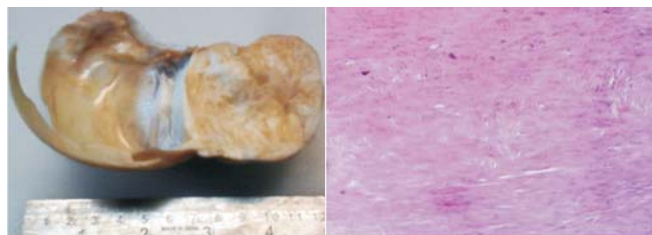
A 65 years old postmenopausal female presented with the chief complaint of intermittent pain and heaviness in lower abdomen. The patient had attained menopause since 17 yrs & had no postmenopausal symptoms. An abdominal examination revealed a large suprapubic mass occupying the lower abdomen. The mass was firm with restricted mobility. Ascites was noted on examination. Hematological & biochemical routine investigations were within normal limits. An abdominal ultrasonography was suggestive of a left ovarian solid and cystic hypoechoic lesion measuring 110 x 102 x 60 mm with associated ascites. Chest X-ray revealed right pleural effusion.

Based on the clinical presentation and radiological findings, a provisional clinical diagnosis of malignant ovarian tumor was considered and the patient

underwent a total abdominal hysterectomy with bilateral salpingo-oophorectomy. Specimen was sent for histopathological examination. About 1.5 liters of ascitic fluid was drained during surgery & sent for cytology analysis. There was complete resolution of ascites & pleural effusion within a few weeks after surgery & postoperative period was uneventful. Cytology smears showed the presence of reactive mesothelial cells with scattered inflammatory cells. No evidence of malignancy was seen.

### Histopathology findings :

**Gross examination :** The specimen consisted of uterus with cervix measuring 6x4x2 cm. Left ovary revealed predominantly solid & partially cystic mass measuring 11 x 9 x 5 cm. Outer surface of the mass was smooth, having intact cystic component. On cutting open, the cyst revealed clear fluid. Cut surface of the solid area was whitish and firm (Fig: 1). Rt. ovary measured 3x2 cm. Both fallopian tubes measured 5 cm in length.



**Figure 1: Gross appearance of ovarian fibroma- Predominantly solid & partly cystic neoplasm. Cut surface of solid area was whitish** **Figure 2: Photomicrograph of ovarian fibroma revealed cytologically bland spindled cells forming vague storiform pattern, 10x view, H & E Stain.**

\* Assistant Professor, Pathology Department, AMC MET Medical College, Ahmedabad

\*\* Resident, \*\*\*Associate Professor, Pathology Department, Smt. NHL Municipal Medical College, Ahmedabad

Correspondence : drbirenparikh@rediffmail.com

**Microscopic examination:** Left ovarian mass revealed proliferation of spindle cells resembling fibroblasts, forming vague storiform pattern (Fig: 2). Cytologic atypia and mitosis were not seen. Hyalinization was present. Uterus, cervix, right ovary & fallopian tubes were unremarkable. Histopathological diagnosis of “fibroma of left ovary” was rendered.

### Discussion :

Sex cord-stromal tumours account for approximately 6% of all ovarian tumors & ovarian fibroma is the most common subtype of sex cord-stromal tumors. <sup>(2)</sup> Fibromas occur at an average age of 48 years and are usually unilateral. <sup>(2)</sup> Fibromas are typically uniformly solid, firm, white neoplasms. The average diameter is 6 cm. Occasionally, tumors are predominantly cystic. Microscopically, fibromas are composed of closely packed spindled stromal cells arranged in a ‘feather-stitched’ or storiform pattern. Hyaline bands, edema, and hyaline globules may be present. <sup>(3)</sup> Cytologic atypia and mitotic activity are usually absent or minor in extent.

The main differential diagnosis in our case was thecoma. Attention to clinico-pathological features of the tumour helps to differentiate between fibroma & thecoma. Grossly, fibromas are solid, uniformly white tumours while thecomas are typically solid yellow masses. Microscopically, the cells of fibroma are spindle shaped resembling fibroblasts while thecoma consists of rounded to polyhedral cells having abundant pale cytoplasm that may be vacuolated due to lipid. <sup>(2)</sup> Thecomas are often associated with estrogenic manifestations. <sup>(2)</sup> Considering all these findings, the diagnosis of fibroma was made. Fibromas and thecomas are both derived from the ovarian stromal cell and because a spectrum exists between the two, some authors use the term “fibrothecoma” for the tumours in the intermediate zone between fibroma and thecoma. <sup>(2)</sup>

The co-existence of pelvic tumour, pleural effusion and ascites has been known since the late 19<sup>th</sup> century. Meigs rediscovered this association and limited it to the ovarian fibroma. Meigs J.V. in 1937 described a syndrome comprising of a fibroma of the ovary with ascites and pleural effusion in a report of 7 cases. <sup>(4)</sup> Finally, in the same year, Rhodes and Terrell denominated it “Meigs syndrome”. <sup>(5)</sup> Following four characteristics were selected by Meigs to define the syndrome: <sup>(4)</sup> 1.) The tumor is a benign fibroma or fibroma like tumor of the ovary. 2.) Ascites. 3.) Pleural

effusion & 4.) Removal of the tumor must cure the patient without recurrence.

The important factor in the formation of ascites & pleural effusion seems to be the tumour size. Fibromas more than 10 cm in diameter are associated with ascites in up to 40% of cases, and Meigs syndrome in approximately 1% of the cases. <sup>(2)</sup>

The pathogenesis for the formation of the pleural and peritoneal effusions is not clearly known. Meigs suggested that the fluid in the abdomen originated from the edematous fibroma that can leak fluid. <sup>(4)</sup> Peritoneal irritation by the tumour may stimulate the production of peritoneal fluid. <sup>(6)</sup> The ascitic fluid can diffuse into pleural cavity. Mechanism for pleural effusion is thought to be related to intrathoracic negative pressure and transdiaphragmatic passage of fluid through peritoneal ‘pores’ or lymphatics. <sup>(3,7)</sup>

### Conclusion :

The constellation of findings consisting of solid ovarian tumour, ascites & pleural effusion should be considered a malignant process until proven otherwise. However, ovarian fibroma may sometimes be presented as a Meigs syndrome comprising of associated findings of ascites & pleural effusion. This association should always be kept in mind while dealing with the classic triad of Meigs syndrome. Considering the good prognosis of Meigs syndrome, prompt and accurate diagnosis is necessary to differentiate the syndrome from other ovarian malignancies.

For ovarian fibroma, oophorectomy is curative & life expectancy is similar to general population.

### References :

1. L. M. Roth, July, 2006 Review. Recent Advances in histopathology & Classification of Ovarian sex cord Stromal Tumors. Int J Gynecol Pathol, Vol 25:199-215.
2. Sternberg’s Diagnostic Surgical Pathology, 5<sup>th</sup> Edition©2010 Lipicott Williams & Wilkins, Ch.55: 4798-4800.
3. Rosai & Ackerman’s Surgical pathology, 10<sup>th</sup> Edition ©201 Elsevire Inc. Ch.19, 1595-97.
4. Meigs JV, Cass JW. “Fibroma of the ovary with ascites and hydrothorax with report of seven cases” .Am J Obstet Gynecol. 1937;33: 249-266.
5. Lurie S. Meigs’s syndrome: the history of the eponym. Eur J Obstet Gynecol Reprod Biol 2000; 92(2): 199-204.
6. Humberto Perez Sarria, Carlos del Rosario Zayas Bazan, John Essien, MD, and Jessica Bardales Mitac, MD. Meigs’ Syndrome: a case presentation and revision of the literature. June 30, 2011, Laparoscopy and Hysteroscopy, Weight Management, Pregnancy and Birth.
7. Sahn SA. The pleura. Is Rev Respir Dis 1988; 138: 184-234.