

Study of Significance of Total Pelvic Height and Pelvic Width in Sex Determination of Human Innominate Bone in Gujarat Region

Sudarshan Gupta^{*} Kiran Arora^{**}

Abstract :

Introduction : Sex determination of the unknown hip bone either of whole skeleton or any part of it, is always a field of research not only for anatomist but also for forensic expert, anthropologist and archeologist. Hip bone was considered as ideal bone for sex determination after skull. **Material and Method :** This study was carried out on 100 dried human innominate bones out of them 40 were female and 60 were male bones. Gross morphometric parameters like total pelvic height, pelvic width was measured and ratio of pelvic width and total pelvic height was calculated. **Results :** Mean value of total pelvic height was higher in male (193.85 mm) compared to female (179.45mm), mean value of pelvic width was also higher in male (137.31 mm) than female (133.24mm). It was found that mean value of ratio between pelvic width and total pelvic height was higher in female (0.74) as compared to male (0.70). The same was found statistically highly significant (P value <0.0001). **Conclusion and Recommendation :** The finding of this study showed that there were statistically significant gender difference were present in gross morphometric parameters, hence these measurements of the hip bone can be used for sex determination of unknown skeletons and in the forensic science for medicolegal cases.

Key Words : Total pelvic height, pelvic width, innominate bone

Introduction :

Innominate bone is also known as hip bone. Sex determination of the unknown either of whole skeleton or any part of it is always a field of research not only for anatomist but also for forensic expert, anthropologist and archeologist. For sex determination of unknown skeleton, skull is the ideal bone. But skull is not always available. In this condition innominate bone was considered as ideal bone for sex determination, because there were various morphological changes in female hip bone, to provide a space for fetal skull during birth process. Hooten^(1,2) states that "the determination of sex from post cranial skeleton in adult is easy and certain in about 80% of the cases, difficult but possible in another 10% of cases and quite dubious in remainder." Many researches have been done on various bones of human skeleton like humerus, femur, clavicle, etc.

There are various methods for sex determination of human innominate bone. One method is by gross morphological anatomy of hip bone like greater sciatic notch, iliac fossa, subpubic arch, inversion of ischiopubic ramus, obturator foramen, preauricular sulcus. Another method is utilizing various measurements of hip bone like

total pelvic height, pelvic width, acetabular diameter, pubic length, measurements of greater sciatic notch. In this study gross morphometric parameters total pelvic height, pelvic width and ratio of pelvic width and total pelvic height were used to show their significance in sex determination of hip bone.

Material and Methods :

This study was done on 100 dried adult human hip bones at Departments of anatomy of different medical colleges in Gujarat state during the year 2007 to 2009.

Damaged, deformed hip bones were excluded from the study. All hip bones were separated in males and females depending on eight visual criteria of human hip bones. Bones those full fill all these criteria were selected for the study. These criteria were:

- 1. Preauricular sulcus⁽³⁾:** Preauricular sulcus was seen or felt as a depression just inferior to auricular part of sacropelvic surface of ilium. This was deeper in female and absent or shallower in male.
- 2. Greater sciatic notch⁽³⁾:** The greater sciatic notch is present posteriorly, bounded above by the ilium, below by the ilium and ischium. It is formed by turning of the posterior border of hip bone horizontally forwards for about 3cm and then turning down and back to join the posterior ischial border. The width and posterior angle of the notch was observed in the entire

* Assistant Professor,
Department of Anatomy, GMERS Medical College, Valsad

** Assistant professor,
Department of Anatomy, GCS Medical College, Ahmedabad
Correspondence : e-mail: drsudarshangupta@yahoo.com

bones. Greater sciatic notch wider in female and narrower in male.

3. **Obturator foramen** ⁽³⁾: The shape of obturator foramen present below and slightly anterior to the acetabulum was noted in both the sexes. The shape of obturator foramen oval in male and triangular in female.
4. **Iliac fossa** ⁽³⁾: The depth of iliac fossa i.e. the internal cavity of ilium forming the wall of greater pelvis was compared in both the sexes. Iliac fossa was deep in male and shallow in female.
5. **Comparison between diameter of acetabulum and the distance of its anterior rim from pubic symphysis** ⁽³⁾: This was done to assess the size of acetabulum in both the sexes. Acetabular diameter was more than distance of its anterior rim from pubic symphysis in male as compared to female.
6. **Ischiopubic ramus eversion** ⁽³⁾: Presence or absence of eversion of ischiopubic ramus was looked for in both the sexes. Ischiopubic ramus was everted in male because of attachment of crus of penis. This was not everted in female.
7. **Subpubic concavity** ⁽³⁾: This was seen from the dorsal aspect as a small curve of the ischiopubic ramus, a short distance below the lower margin of pubic symphysis. Subpubic concavity was present in female and absent in male.
8. **Ventral arc** ⁽⁴⁾: Ventral arc was seen as a slightly elevated ridge of bone starting from pubic crest and extending inferiorly across the ventral surface of body of pubis, blending with the medial border of ischiopubic ramus. Ventral arc was seen in female, not in male.

By these criteria 40 female and 60 male hip bones were selected for study. Out of 40 female hip bones, 26 were right and 14 were left side hip bones. Out of 60 male hip bones, 37 were right and 23 were left hip bones.

Total pelvic height was measured with the help of osteometric board and pelvic width with vernier caliper.

Measurement specification :

1. **Total pelvic height** ⁽⁵⁾(TPH) : This longest hip bone dimension was measured from the highest point on the

iliac crest to the deepest point of ischial tuberosity (inferior most point on iliac tuberosity).For the measurement of TPH used the osteometric board as shown in the fig.1.

2. **Pelvic (iliac) width** ⁽⁶⁾ (PW) : Pelvic width was measured as straight distance from anterior superior iliac spine to posterior superior iliac spine like fig.2.

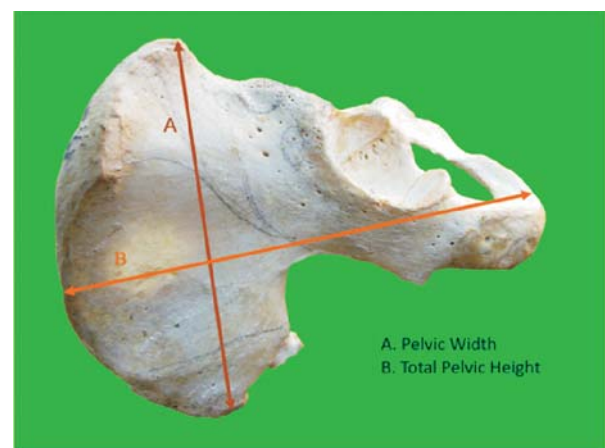
3. Ratio of pelvic width and total pelvic height (PW/TPH) was calculated as fig.2.

All these parameters were analyzed statistically.

Figure 1: Showing method of measurement of total pelvic height of right hip bone with the help of osteometric board.

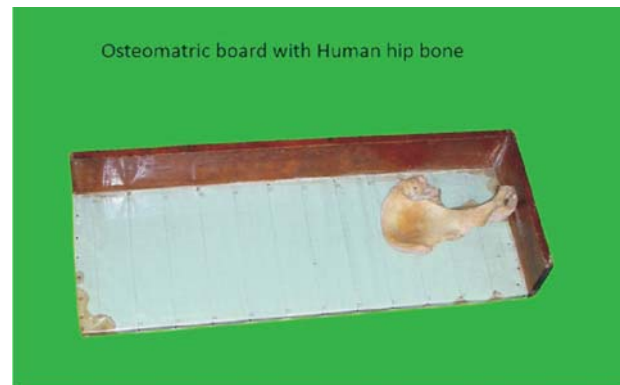

Figure 2: showing bony point on hip bone from where these measurements had been taken.



Results :

All measurements were analyzed and their mean standard deviation was calculated. "t test" was applied to find out significance of these differences in male and female hip bones. In table 1, 2 and 3 results of these measurements were shown.

Table 1: Measurements of parameters of male hip bones

Parameters	Male Hip bones Total number - 60		Minimum (In mm)	Maximum (In mm)
	Mean	SD		
Total pelvic height (TPH)	193.85	9.15	173	215
Pelvic Width (PW)	137.31	7.18	121.4	150
PW/TPH	0.70	0.024	0.6609	0.7712

Table 2: Measurements of parameters of female hip bones

Parameters	Female Hip bones Total number - 40		Minimum In mm	Maximum In mm
	Mean (In mm)	SD		
Total pelvic height (TPH)	179.45	9.94	157	204
Pelvic Width (PW)	133.24	7.35	112.3	155.2
PW/TPH	0.74	0.036	0.6644	0.8484

After comparison between table 1 and 2 mean of total pelvic height in female (179.45mm) was less as compared to male(193.85 mm) and mean of pelvic width was also less in female 133.24 mm as compared to male(137.31 mm) hip bone. But ratio between pelvic width and total pelvic height was more in female.

Table 3: Comparison of parameters in male and female hip bones

Parameters	Female v/s Male	
	T test	P value
Total pelvic height (TPH)	7.448	P < 0.0001
Pelvic Width (PW)	2.751	P < 0.0071
PW/TPH	6.672	P < 0.0001

After applying t- test P value of total pelvic height was P < 0.0001 (Highly significant), pelvic width P < 0.0071 (Highly significant), P value of PW/TPH P < 0.0001 (Highly significant).

Discussion:

Determination of sex of unknown human skeleton is a challenging task for forensic expert and archeologist. Many studies have been done on skeletal material by various researchers for sexing of bone. Hip bone is having great value in sexual dimorphism.

Various techniques have been employed by researchers for sex determination of hip bone. These techniques include visual criteria, objective criteria or analytical criteria. Visual

criteria for sex determination of hip bone are having high degree of subjective error and it requires experience. For Objective criteria, no standard charts are available for various parameters and different races.

In this study 100 adult human hip bones of unknown sex were selected. By 8 visual criteria these hip bones were categorized into male and female hip bones. Out of these 100 hip bones, 60 were male and 40 were female hip bones.

The result of our study showed that mean of total pelvic height and pelvic width was higher in male as compared to female and the difference was statistically significant.

Mean value of Ratio of total pelvic width and total pelvic height was also highly significant and higher in female.

Our results were similar to the finding of Segebarth – Orban,⁽⁷⁾ whose study also stated that total pelvic height and iliac width were significantly larger in male.

Davivongs et al⁽⁸⁾ study in Australian Aborigine pelvis showed that total pelvic height and pelvic width were significant and the significance of sex differences of these parameters was high but the male and female ranges overlapped. This was also found in present study.

Camacho et al⁽⁹⁾ observed the mean values of pelvic width and found that there were no significant difference of mean between male and female.

Conclusion :

This study showed that mean values of total pelvic height

Gupta S and Arora K: Human Innominate Bone in Sex Determination

and pelvic width and ratio of pelvic width and total pelvic height was statistically highly significant. Mean of total pelvic height and pelvic width was more in male and mean of ratio of pelvic width and total pelvic height was more in female. But there was overlapping between the range of total pelvic height and pelvic width in male and female. This overlapping can be minimized by considering the ratio of these two parameters.

References :

1. Hooton, E.A., 1946, Up from the ape, revised Macmillan Co. New York
2. Gopal Sharma. Evaluation the various criteria of sex determination of hip bone of Jhalawar region of Rajasthan, India. *J Pharm Biomed Sci*, 2013, January, 26(26) 330-335.
3. Bannister LH, Beny MM, Collins P, Dyson M, Dussek JE. Ferguson MWJ, editors. *Gray's Anatomy*. 38th ed. London: Churchill Livingstone; 2000. p.663-74.
4. Phenice TW. A newly developed method of sexing the os pubis. *Am J phys Anthropol* 1969;30:297-302.
5. Patriquim ML, Steyn M, Loth SR Metric analysis of sex difference in South African black and white pelvis. *Forensic Sci mt* 2005;147: 119-27.
6. Milne N. Sexing of hip bones. *J Anat* 1990; 172:221-26.
7. Segebarth – Orban R. An evaluation of the sexual dimorphism of the human innominate bone. *J Hum Evol* 1980 Dec;9(8):601-07.
8. Davivongs V. The pelvic girdle of Australian Aborigine: Sex determination. *Am J Phys Anthropol* 1963; 21:443-55.
9. Comacho FJF, Pellico LG, Rodriguez RFV. Osteometry of the human iliac crest: Patterns of normality and its utility in sexing human remains. *J Forensic Sci* 1993; 38(4):779-87.