

A cadaveric study of origin of inferior phrenic artery form celiac trunk

Bharat G Patel*, Prakash Gosai**, Ritesh K Shah***, Sanjay D Kanani****

Abstract :

Introduction : The inferior phrenic arteries (IPA) constitute a pair of important vessels, supplying multiple organs including the diaphragm, adrenal glands, esophagus, stomach, liver, inferior vena cava, and retroperitoneum. Infrequently, the right and left inferior phrenic arteries can arise in the form of a common trunk from the aorta or from the celiac trunk. It employs the most frequent origin of extrahepatic arterial blood source in hepatocellular carcinoma (HCC). Due to very less information concerning the IPA and their importance in the arterial supply and growth of HCC, these arteries have received increased attention in the recent years. The present study is undertaken to know the percentage of origin of inferior phrenic arteries from the celiac trunk. **Methods :** The study was conducted on 39 cadavers from the dissection laboratory with an age range of 50 – 80 years. The cadavers were embalmed through carotid arterial perfusion of formaldehyde solution, spirit, water and glycerin and preserved in a weak formalin solution before dissection. Dissection method was employed for this study.

Result and Observation : In 16(41%) cadavers, the inferior phrenic arteries had their origin from coeliac trunk. Out of the 16 cadavers, right inferior phrenic artery (RIPA) alone arising from the coeliac trunk was present in 2(05%) cadavers, left inferior phrenic artery (LIPA) alone in 12(30.77%) cadavers and both IPA in 2(05%) cadavers. **Conclusion :** The knowledge of variation of inferior phrenic artery origin shows that surgeons must be cautious to avoid unintentional sectioning of small caliber arteries, as it may occur during the coeliac artery decompression in the compression syndrome of the coeliac trunk by the median arcuate ligament. Finding in this study could be applied in treatment of HCC. An unresectable HCC can be treated by transcatheter embolization of right inferior phrenic artery, in case it is involved.

Key Words : Coeliac trunk, Inferior phrenic artery, Hepatocellular carcinoma

Introduction :

The inferior phrenic arteries(IPA) constitute a pair of important vessels; supplying multiple organs including the diaphragm, adrenal glands, esophagus, stomach, liver, inferior vena cava, and retroperitoneum.⁽¹⁾ The vast majority of inferior phrenic arteries originate as separate vessels from either the abdominal aorta or the celiac trunk. Infrequently, the right and left inferior phrenic arteries can arise in the form of a common trunk from the aorta or from the celiac trunk. However, variation in IPA origin is a rule, rather than an exception. In Adachi's study⁽²⁾ of 74 cadavers, the artery arose from the abdominal aorta and the coeliac trunk in 31 and 34 cadavers, respectively. A total of 383 computed tomography images by Gwon showed that the site of IPA origin was the celiac trunk and aorta in 152 and 148 cases, respectively. The IPA is the most common source of extra hepatic collateral blood supply for HCC and frequently supplies HCC located in

the bare area of the liver.⁽³⁾ The knowledge of the arterial anatomical variations is very important for clinical, radiological and surgical diagnosis.

Material and method :

This study was conducted on 39 cadavers from the dissection laboratory with an age range of 50 – 80 years. The cadavers were embalmed through carotid arterial perfusion of formaldehyde solution, spirit, water and glycerin and preserved in a weak formalin solution before dissection. The dissection was performed in dissection laboratories of GCS Medical College, Ahmedabad, AMC MET Medical College Ahmedabad from 2010 to 2012. Routine manual dissection was done to open abdomen following the instruction of Cunningham's manual. After removal of the lesser omentum, the proximal part of abdominal aorta and its branches were traced out. Later, after the removal of stomach and pancreas, the origins of the IPA were confirmed. The frequency and anatomical pattern of the origin of the right and left inferior phrenic arteries were observed and noted.

Results :

Out of 39 cadavers studied the inferior phrenic arteries had their origin from coeliac trunk n 16(41%) cadavers. Right

* Associate Professor,
*** Assistant Professor,
**** Tutor, Department of Anatomy,
GCS Medical College, Ahmedabad, Gujarat, India
** Jr. Lecturer, Department of Anatomy,
AMC MET Medical College, Ahmedabad, Gujarat, India
Correspondence : drbgpatel67@gmail.com

inferior phrenic artery (RIPA) alone arising from the coeliac trunk was present in 2(05%) cadavers. Left inferior phrenic artery (LIPA) alone arising from the coeliac trunk was present in 12(30.77%) cadavers. Both RIPA and LIPA arising from the coeliac trunk were present in 2(05%) cadavers. In rest of 23(58.97%) cadavers RIPA and LIPA takes origin from abdominal aorta. Table.1 shows percentage of various origin of inferior phrenic artery

Table1 : Percentage of various origin of inferior phrenic artery

Site of origin of IPA	Number of cadavers (n=39)
From Aorta	23 (58.97 %)
RIPA alone from celiac trunk	02 (05 %)
LIPA alone from celiac trunk	12 (30.77 %)
Both IPA from celiac trunk	02 (05 %)

Figure.1 RIPA from celiac trunk (1-Celiac trunk, 2-Splenic artery, 3-Common hepatic artery, 4-Left gastric artery, 5-RIPA)

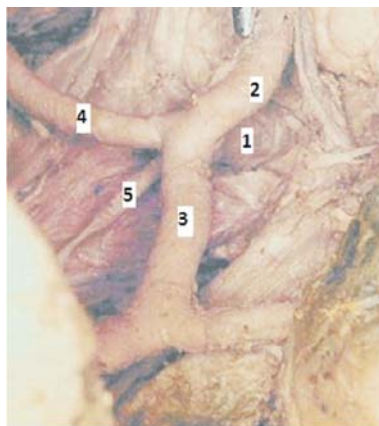


Figure.2 LIPA from celiac trunk (1-Celiac trunk, 2-Splenic artery, 3-Common hepatic artery, 4-Left gastric artery, 5-LIPA)

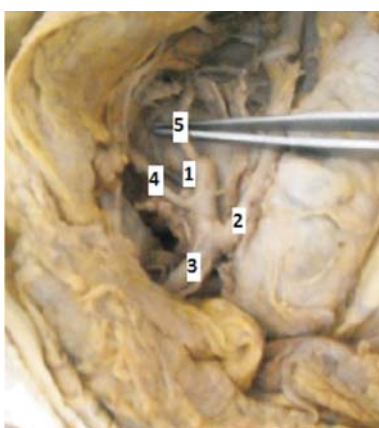
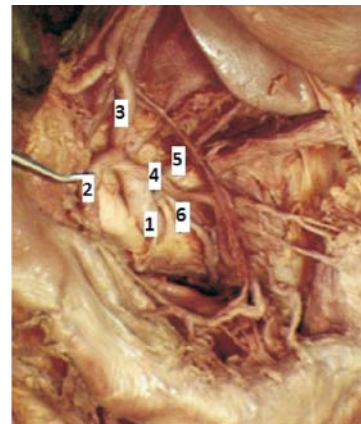


Figure.3 Both RIPA and LIPA from celiac trunk (1-Celiac trunk, 2-Splenic artery, 3-Common hepatic artery, 4-Left gastric artery, 5-RIPA, 6-LIPA)



Discussion :

Keeping in view the aim of the study mentioned earlier, following observations were recorded:

Table.2 shows comparison of percentage of various origins of RIPA and LIPA. Previous study done by Petrella⁽⁴⁾ shows origins of RIPA alone from celiac trunk in 5.62%, LIPA alone from celiac trunk in 21.35%, both RIPA and LIPA from celiac trunk in 7.86%. Pulakunta⁽⁵⁾ shows origins of LIPA alone from celiac trunk in 3.125%, both RIPA and LIPA from celiac trunk in 3.125%. In present study shows origins of RIPA alone from celiac trunk in 05%, LIPA alone from celiac trunk in 30.7 % , both RIPA and LIPA from celiac trunk in 05%. The origin of RIPA and both RIPA & LIPA from celiac trunk seen in present study is lower than Petrella’s study but origin of LIPA from celiac trunk is higher. Rawat⁽⁶⁾ observed RIPA alone arising from celiac trunk in 2 cases (1.6%) and both RIPA & LIPA arising from celiac trunk in 1 case (0.8%) from 125 angiographies. Mburu⁽⁷⁾ finds origin of IPA fro celiac trunk in 4.9% cases from 123 specimens.

Table 2 : Comparison of percentage of various origin of RIPA and LIPA

Site of origin of IPA	Petrella ⁽⁴⁾ (89 cadavers)	Pulakunta ⁽⁵⁾ (32 cadaves)	Present Study (39 cadavers)
RIPA alone from celiac trunk	5.62 %	-	05 %
LIPA alone from celiac trunk	21.35 %	3.125 %	30.77 %
Both IPA from celiac trunk	7.86 %	3.125 %	05 %

The inferior phrenic arteries have received increased attention in recent years after the discovery of involvement of RIPA or LIPA in arterial supply and growth of HCC. The IPA is major source of collateral arterial supply of HCC. The great importance of such knowledge in an unrespectable HCC can be treated as transcatheter embolization of RIPA or LIPA if involved. The interventional radiologist or oncologist needs to identify the origin of RIPA during transcatheter embolization of HCC.

Embryologically, the celiac trunk and IPA derived from 6th pair of ventral splanchnic vessels. During foetal development, these pairs span and disappear, but if longitudinal channels between primitive vessels persist may lead to vascular variations.⁽⁸⁾ Trauma to IPA can cause hemoperitoneum, haemoptysis, or gastroesophageal, diaphragmatic, or hepatic bleeding. In setting of several occlusive vascular diseases these vessels constitute an important source of collateral flow to the intestinal circulation and can provide crucial renal perfusion.^(9,10)

Conclusion :

All interventionalists associated with transcatheter arterial chemoembolization of HCC or gastroesophageal bleeding management using embolization need to aware of this variant anatomy to prevent nontarget embolization. The knowledge of variation of inferior phrenic artery origin shows that surgeons must be cautious to avoid unintentional sectioning of small caliber arteries, as it may occur during the celiac artery decompression in the compression syndrome of the celiac trunk by the median arcuate ligament.

Acknowledgement :

We sincerely thankful to our Professor and Head of the Department of Anatomy, GCS Medical College and AMC MET Medical College, Ahmedabad, who not only acted as guide but also as a mentor for successfully completing this research.

References :

1. Topaz O, Topaz A, Polkampally PR, Thomas Damiano, Christopher A. King. Origin of a common trunk for the inferior phrenic arteries from the right renal artery: a new anatomic vascular variant with clinical implications. *Cardiovascular Revascularization Medicine*: 2010; 11: 57-62.
2. Adachi B. *Das Arteriensystem der Japaner*. Kyoto: Verlag der Kaiserlich-Japanischen Universität zu Kyoto. Tokyo: Kenyusha Press, 1928.
3. Gwon D, Ko G, Yoon H, Sung K, Lee FM, Ryu SF. Inferior phrenic artery: Anatomy, variations, pathologic conditions and interventional management. *Radiographics*: 2007;27:687-705.
4. Petrella S, Rodrigues CFS, Sgrott EA, Fernandez GJM, Marques SR, Prates JC. Origin of inferior phrenic arteries in the celiac trunk. *Int. J. Morphology*: 2006;24(2):275-278.
5. Pulakunta T, Potu BK, Gorantla VR, Rao MS, Madhyastha S, Vollala VR. The origin of the inferior phrenic artery: a study in 32 south Indian cadavers with a review of literature. *J Vasc Bras*: 2007;6(3):225-230.
6. Rawat KS. CTA in evaluation of vascular anatomy and prevalence of vascular variants in upper abdomen in cancer patients. *Ind J Radiol Imag*: 2006;16:4:457-461.
7. Mburu KS, Alexander OJ, Hassan S, Bernard N. Variations in the branching pattern of celiac trunk in Kenyan population, *Int. J. Morphology*: 2010;28(1):199-204.
8. Murakami T, Ohtsuka A, Piao DX. Typology of the human celiac, left gastric, splenic, hepatic, superior mesenteric, inferior mesenteric and inferior phrenic arteries. *Okayama Igakkai Zasshi*: 1995; 107:219-26.
9. Loukas M, Hullett J, Wagner T. Clinical anatomy of the inferior phrenic artery. *Clinical anatomy*: 2005; 18:357-65.
10. Lee JW, Kim S, Kim CW, Jeon Ty. Massive hemoperitoneum due to ruptured inferior phrenic artery pseudo aneurysm after blunt trauma. *Emerg Radiol*: 2006; 13:147-9.

Abbreviation used

- HCC – Hepato Cellular Carcinoma
 IPA – Inferior Phrenic Artery
 RIPA – Right Inferior Phrenic Artery
 LIPA – Left Inferior Phrenic Artery