

Paget's disease of Breast Masquerading As Chronic Eczema – Report of Two Cases with Review of Literature

Anupama Dayal*, Puja Jarwani**, S M Patel***

Abstract :

Paget's disease of the breast is a relatively rare oncologic entity in women and even rarer in men. It should be looked for with high index of suspicion at all unilateral lesions presenting as chronic eczematous lesion of nipple-areola complex. The breast examination should search for an underlying breast neoplasm. Histopathological examination is confirmatory for the diagnosis. We report cases of two patients with Paget's disease of the breast, and underline the importance of early diagnosis and management.

Keywords : Paget's disease, eczema, breast, histopathology

Introduction :

Paget's disease of the breast presents as an erythematous, scaly lesion affecting the nipple and the areola and extending to the periareolar region. This condition has been documented in patients of 26 to 82 years of age; however, it occurs predominantly in patients of 40-60 years of age and is rarely found in younger patients. ⁽¹⁾ Mammary Paget's disease accounts for 2-3% of neoplastic conditions of the breast. In most cases (82-92% in several studies) tumour cells have spread to skin of the nipple and areola from underlying invasive carcinoma or ductal carcinoma in situ. Rare cases appear to have originated primarily within the nipple epidermis. ⁽²⁾ We report two cases of Paget's disease of the nipple-areola complex, one with an underlying multicentric ductal cell carcinoma and other with no evidence of underlying breast carcinoma.

Case 1

A 48 year old female presented with an ulcerative lesion causing erosion of the nipple-areola complex of left breast (Figure 1A). The lesion had started two and half years back and was given treatment with topical steroids considering it as an eczematous lesion, by which it subsided partially. Subsequently, since last two months, the lesion rapidly progressed to cause ulceration and nipple deformity. On physical examination, a firm, non-tender, small lump (1.0x0.5 cm) was palpable in retroareolar region. Mammography showed pleomorphic microcalcifications and a small spiculated density in retroareolar region of left breast. FNA showed features of mammary carcinoma and possibility of Paget's disease with underlying ductal carcinoma of breast was given.

MRM was performed and gross examination revealed multicentric tumour masses, most prominent in the subareolar region. On histopathology, Paget's cells with abundant amphophilic finely granular/vacuolated cytoplasm, central nuclei with prominent nucleoli were seen permeating singly and in clusters in all layers of the epidermis (Figure 1B). Underlying breast tissue showed ductal cell carcinoma (Figure 1C). IHC was S-100 negative; Her-2-neu positive with focal positivity for CEA (Figure 2). ER, PR was negative.

Figure 1: (A) Shows ulcerative lesion causing erosion of the nipple-areola complex of left breast (B) Shows large atypical cells permeating the epidermis (C) Shows underlying area of ductal cell carcinoma.

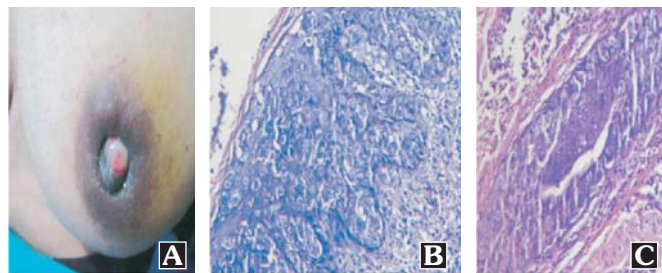
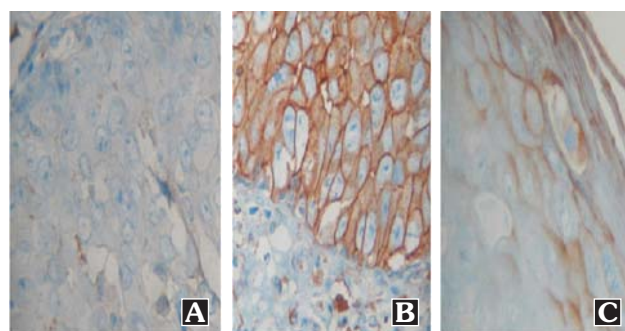


Figure 2 : Immunohistochemistry(Case 1);(A) S-100 negative (B) Her2neu Positive(C)CEA focal positive



* Assistant Professor

** Tutor

*** Professor & Head, Pathology Department, GCS Medical College Hospital & Research Centre, Ahmedabad, Gujarat, India

Correspondence : e-mail: pujabhavesh@hotmail.com

Case 2

80 yrs old female patient presented with eczematous skin lesion with itching for 7-8 months. On physical examination right breast showed single well defined eczematized plaque with areas of central clearing and destruction of the nipple with no palpable lump. B/L accessory axillary breast was also present (Figure 3A). Mammogram showed mild areolar skin thickening in right breast while bilateral axillary accessory breast tissue showed normal fatty parenchyma. There was no evidence of any focal mass lesion. Scraping from the skin lesion and FNAC from retroareolar region was done but the smears showed only few keratin squames and inflammatory cells. Skin biopsy showed presence of few large, round cells with large nucleus and abundant clear to pale eosinophilic cytoplasm, prominent nucleoli and loss of intercellular bridges permeating the epidermis.

Right mastectomy was done. Grossly there was eroded and ulcerated nipple and areola with no evidence of any lump. Histopathology of the nipple areola complex confirmed the biopsy findings and showed marked intra epidermal permeation by atypical large round to oval cells (Figure 3B & C). Rest of the breast parenchymal tissue showed presence of focal irregular fibrosis with focal fibrocystic change .IHC showed these cells to be S-100 negative, Her2neu positive and CEA focally positive confirming it to be Paget's disease of breast (Figure 4).

Figure 3: (A) Right breast shows eczematized plaque with areas of central clearing and destruction of the nipple, no palpable lump with B/L accessory axillary breast (B) Shows large atypical cells permeating the epidermis(C) Shows high power view; Paget's cells with abundant amphophilic finely granular/vacuolated cytoplasm, central nuclei with prominent nucleoli

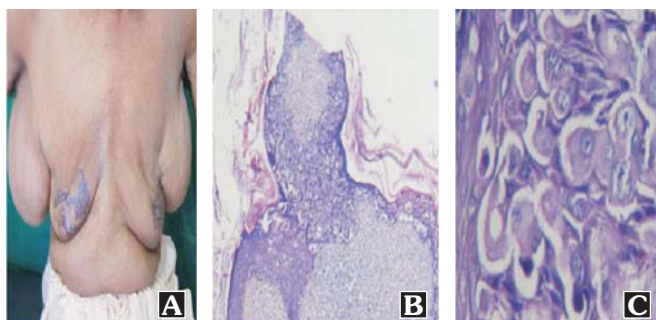
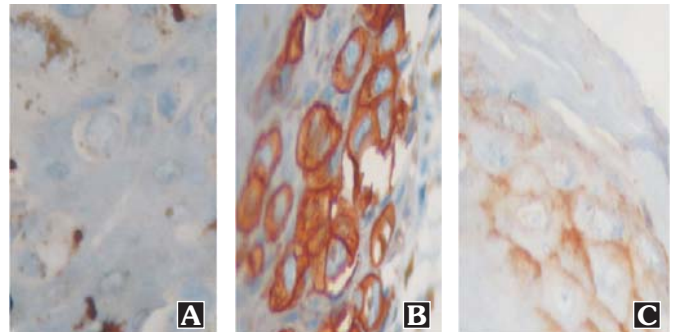


Figure 4 : Immunohistochemistry (Case 2);(A) S-100 negative (B) Her2neu Positive(C)CEA focal positive



Discussion :

Paget's disease of the breast is a malignant condition that outwardly presents as an eczematous lesion of the nipple areola skin. Since the presentation is innocuous and limited to a surface appearance, it is sometimes dismissed, although actually indicative of a very serious condition, possibly underlying breast cancer.⁽³⁾

Two theories have been formulated to explain Paget's disease of the breast:

The epidermotropic theory: Paget's cells originating in the apocrine duct are transformed into ductal carcinoma and migrate to the epithelium of the nipple. This would explain the cases of Paget's disease with an underlying intraductal carcinoma.⁽⁴⁾ This is supported by the observation that Paget cells often share cell surface markers with the underlying breast carcinoma (e.g CAM 5.2, CEA, c-erb 2 and EMA).^(5, 6) Normal epidermal keratinocytes produce and release the mobility factor heregulin-alpha which is chemotactic for heregulin receptors (Her-2) and coreceptors Her 3 and Her 4 which are produced by Pagets cells. This is thought to result in migration of these cells to the nipple epidermis.⁽⁷⁾

The transformation theory: Paget's cell is a transformed malignant keratinocyte, which suggests that Paget's disease is an independent carcinoma in situ. This would explain the cases of the disease in which no identifiable breast carcinoma is present, as is found in some rare cases.⁽⁴⁾

The clinical features usually simulate benign eczema, psoriasis or dermatitis, resulting in treatment with topical steroids as in case.1.The reported median delay in diagnosis is about 6-11 months.⁽⁶⁾ Points which help to differentiate from eczema include : unilateral presentation, involves nipple first, less intense pruritus, progressive in

course with inadequate response to corticotherapy.⁽⁴⁾ The diagnostic microscopic feature of Paget's disease is presence of large tumour cells lying singly or in small clusters within the epidermis having abundant finely granular cytoplasm.⁽⁸⁾ On immunohistochemistry Paget's cells are CEA and CK7 positive which helps to differentiate from Bowen's disease. Malignant melanoma can also be ruled out as Paget's cells are negative for melanoma markers such as S-100 and HMB-45.⁽²⁾ It has now been established that Paget's cells exhibit glandular differentiation as seen by the similarities in immunohistochemical profile and oncogene expression (such as Her2/neu or RAS 21).⁽⁹⁾

Ceccherini et al. reported that mammography did not discriminate between DCIS and invasive disease nor could it predict their subtype. In addition, mammography cannot map the true distribution of the underlying pathology and is therefore of limited value in determining the appropriate surgical procedure.⁽¹⁰⁾ These two cases underline the importance of high index of suspicion and early skin biopsy/ cytology in persistent eczematous lesion of nipple. Early diagnosis is important as untreated lesions progress to present as a lump, followed by lymph node involvement as is highlighted in the first case. In conclusion, Paget's disease remains an elusive clinical diagnosis due to its varied presentations, ranging from change in sensation, itching, and burning, to ulceration and destruction of the nipple-areola complex. Awareness of the clinical presentation and pathogenesis of this uncommon condition alerts the clinician to search for underlying carcinoma, which facilitates early detection and treatment, with better prognosis.

Acknowledgement :

We are thankful to Dr.S.N.Shukla, Director, GCRI, Ahmedabad for IHC of both the cases and Dr. R.I. Dave, HOD, Surgery Department, GCS Medical College, Ahmedabad for the clino-pathological correlation.

References :

1. Lage D, Volpini CA, Sasserone MG, Daldon P, Arruda L. Paget's Disease: The importance of the specialist. *An Bras Dermatol*. 2010; 85(3):365-9.
2. Lloyd J, Flanagan AM. Mammary and extramammary Paget's disease. *J Clin Pathol* 2000; 53:742-9.
3. Karakas C. Paget's disease of the breast. *J Carcinog* 2011; 10:31
4. Azulay L, Bonalumi A, Azulay DR, Leal F. Atlas de dermatologia: da semiologia ao diagnostico. Rio de Janeiro: Elsevier; 2007.
5. Meissner K, Riviere A, Haupt G, Loning T: Study of neu-protein expression in mammary Paget's disease with and without an underlying breast carcinoma and in extramammary Paget's disease. *American Journal of Pathology* 1990, 137(6):1305-9.
6. Valdes EK, Feldman SM: Paget's disease of the breast. *The Breast Journal* 2006, 12(1):83.
7. Schelfhout VR, Coene ED, Delaey B, Thys S, Page DL, De Potter DR: Pathogenesis of Paget's disease: epidermal heregulin-alpha, motility factor, and the HER receptor family. *J Natl Cancer Inst* 2000, 92(8):622-8
8. Kumar V, Abbas AK, Fausto N, Aster JC. Robbins and Cotran Pathologic Basis of Disease. 8th ed. Elsevier publishers; 2010: 1015
9. Rosai J. Rosai and Ackerman's Surgical Pathology. 10th ed. Elsevier publishers; 2012: 1707-1708
10. Ceccherini AF, Evans AJ, Pinder SER, Wilson AR, Ellis IO, Yeoman LJ. Is ipsilateral mammography worthwhile in Paget's disease of the breast? *Clin Radiol*. 1996; 51: 35-38.